This is a digital copy of a book that was preserved for generations on library shelves before it was carefully scanned by Google as part of a project to make the world's books discoverable online.

It has survived long enough for the copyright to expire and the book to enter the public domain. A public domain book is one that was never subject to copyright or whose legal copyright term has expired. Whether a book is in the public domain may vary country to country. Public domain books are our gateways to the past, representing a wealth of history, culture and knowledge that's often difficult to discover.

Marks, notations and other marginalia present in the original volume will appear in this file - a reminder of this book's long journey from the publisher to a library and finally to you.

Usage guidelines

Google is proud to partner with libraries to digitize public domain materials and make them widely accessible. Public domain books belong to the public and we are merely their custodians. Nevertheless, this work is expensive, so in order to keep providing this resource, we have taken steps to prevent abuse by commercial parties, including placing technical restrictions on automated querying.

We also ask that you:

+ *Make non-commercial use of the files* We designed Google Book Search for use by individuals, and we request that you use these files for personal, non-commercial purposes.

+ *Refrain from automated querying* Do not send automated queries of any sort to Google's system: If you are conducting research on machine translation, optical character recognition or other areas where access to a large amount of text is helpful, please contact us. We encourage the use of public domain materials for these purposes and may be able to help.

+ *Maintain attribution* The Google "watermark" you see on each file is essential for informing people about this project and helping them find additional materials through Google Book Search. Please do not remove it.

+ *Keep it legal* Whatever your use, remember that you are responsible for ensuring that what you are doing is legal. Do not assume that just because we believe a book is in the public domain for users in the United States, that the work is also in the public domain for users in other countries. Whether a book is still in copyright varies from country to country, and we can't offer guidance on whether any specific use of any specific book is allowed. Please do not assume that a book's appearance in Google Book Search means it can be used in any manner anywhere in the world. Copyright infringement liability can be quite severe.

About Google Book Search

Google's mission is to organize the world's information and to make it universally accessible and useful. Google Book Search helps readers discover the world's books while helping authors and publishers reach new audiences. You can search through the full text of this book on the web at `http://books.google.com/`

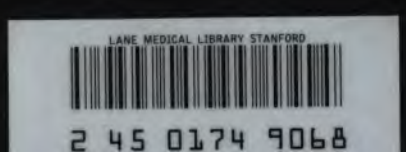
LANE MEDICAL LIBRARY STANFORD
2 45 0174 9068

JUL 5 1967

LANE

MEDICAL LIBRARY

Gift

LANE MEDICAL LIBRARY
300 PASTEUR DRIVE
PALO ALTO, CALIFORNIA 94304

1914

THE TONSILS

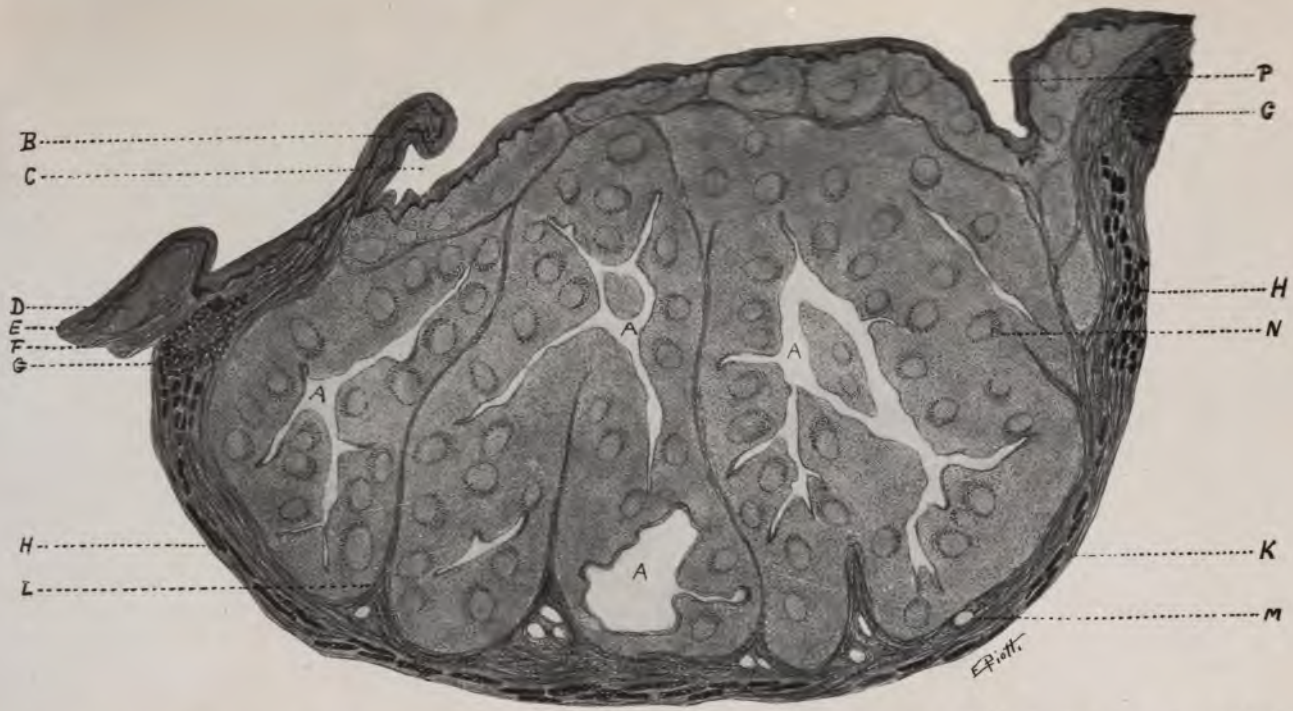

Cross-section of human tonsil, age eleven years, dissected out in capsule. X 10. This tonsil was moderately hypertrophied, with crypts greatly dilated and filled with detritus. It represents a condition found in a large percentage of the hypertrophied tonsils of childhood.

A, Crypts, very irregular and dilated; B, Plica triangularis; C, Anterior fossa; D, Lymphoid follicles outside capsule; E, Surface epithelium; F, Tunica propria of surface mucosa; G, Mucous glands; H, Muscle fibers of capsule; K, Capsule; L, Trabecula; M, Blood vessel; N, Lymphoid follicle with germinal center; P, Posterior fossa.

THE TONSILS

FAUCIAL, LINGUAL, AND PHARYNGEAL

WITH SOME ACCOUNT OF THE POSTERIOR AND LATERAL PHARYNGEAL NODULES.

BY

HARRY A. BARNES, M. D.

INSTRUCTOR IN LARYNGOLOGY, HARVARD MEDICAL SCHOOL; SURGEON IN THE DEPARTMENT FOR DISEASES OF THE NOSE AND THROAT, BOSTON DISPENSARY; ASSISTANT LARYNGOLOGIST, MASSACHUSETTS GENERAL HOSPITAL; MEMBER NEW ENGLAND LARYNGOLOGICAL AND OTOLOGICAL SOCIETY; MEMBER AMERICAN LARYNGOLOGICAL, RHINOLOGICAL AND OTOLOGICAL SOCIETY.

ILLUSTRATED

ST. LOUIS
C. V. MOSBY COMPANY
1914

LANE LIBRARY. STANFORD UNIVERSITY

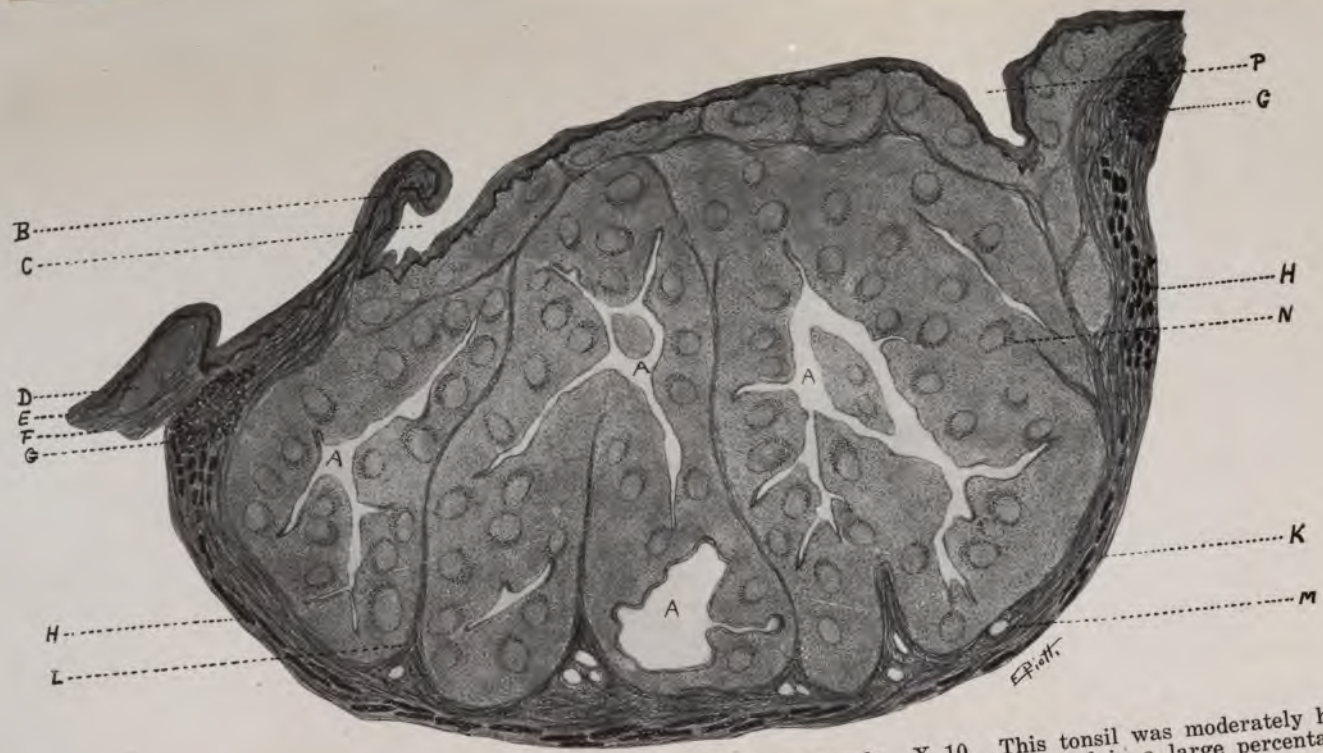

Cross-section of human tonsil, age eleven years, dissected out in capsule. X 10. This tonsil was moderately hypertrophied, with crypts greatly dilated and filled with detritus. It represents a condition found in a large percentage of the hypertrophied tonsils of childhood.

A, Crypts, very irregular and dilated; B, Plica triangularis; C, Anterior fossa; D, Lymphoid follicles outside capsule; E, Surface epithelium; F, Tunica propria of surface mucosa; G, Mucous glands; H, Muscle fibers of capsule; K, Capsule; L, Trabecula; M, Blood vessel; N, Lymphoid follicle with germinal center; P, Posterior fossa.

THE TONSILS

FAUCIAL, LINGUAL, AND PHARYNGEAL

WITH SOME ACCOUNT OF THE POSTERIOR AND LATERAL PHARYNGEAL NODULES

BY

HARRY A. [illegible], M.D.

COPYRIGHT, 1914, BY C. V. MOSBY COMPANY

Press of
C. V. Mosby Company
St. Louis

K56
B26
1914

TO

WILLIAM THOMAS COUNCILMAN, A.M., M.D., LL.D.,

SHATTUCK PROFESSOR OF PATHOLOGICAL ANATOMY,

MEDICAL SCHOOL OF HARVARD UNIVERSITY,

WHO INITIATED ME INTO THE STUDY OF THE LYMPHOID TISSUES

THIS BOOK IS RESPECTFULLY INSCRIBED.

PREFACE.

During the past few years the tonsils have held such a prominent place in the periodical medical press, as seemingly to make unnecessary a book devoted to them. Yet this mass of literature is not entirely satisfactory, both on account of its bulk and because of the wide divergence of opinion on certain phases of the subject. This book lays no claim to having settled any of the mooted questions. It is an attempt to put into concise form the facts concerning the lymphoid tissues of the throat, and to make these facts the basis of any theories advanced. The more strictly scientific parts have been written with a view to emphasizing their practical application to clinical work. I hope they have lost nothing of their scientific value on that account.

The illustrations in the book are all original. Many of the histological plates are from photo-micrographs; others are from drawings by Miss Etta R. Piotti, and are faithful representations of typical microscopic fields. The drawings illustrating operative technique are by Miss D. P. Blair, and are the result of personal observation in the operating room. I have to thank both Miss Piotti and Miss Blair for their excellent work. My thanks are also due Dr. J. L. Goodale for suggesting my name to the publishers, as one likely to have the material for a book on the tonsils; Dr. Charles S. Minot and Dr. John Warren of the Harvard Medical School for embryological material; and

Dr. A. Coolidge, Jr., Chief of the Laryngological Staff, Massachusetts General Hospital, for kindly reading parts of the book in manuscript.

HARRY A. BARNES.

BOSTON, July, 1914.

CONTENTS.

CHAPTER I. PAGE

THE GENERAL NATURE OF LYMPHOID TISSUE 17–20

CHAPTER II.

THE DEVELOPMENT OF THE TONSIL 21–28

The Development of the Crypts—The Lymphoid Tissue—The Root of the Tonsil—The Development of the Fossæ—The Development of the Capsule—Histogenesis of the Tonsil.

CHAPTER III.

THE ANATOMY AND HISTOLOGY OF THE TONSILS 29–54

The Anatomy and Histology of the Faucial Tonsil—The Crypts—The Sinus Tonsillaris—The Plicæ—The Root of the Tonsil—The Superior or Supratonsillar Fossa—The Anterior Fossa—Posterior Fossa—The Capsule—Types of Tonsil—The Blood Supply of the Tonsils—The Lymphatics of the Tonsils—The Nerve Supply of the Tonsils—The Relations of the Tonsil—The Normal Histology of the Tonsil—The Capsule—The Crypts—The Epithelium—The Hypertrophied Tonsil—What Constitutes Hypertrophy of the Tonsils?—The Causes of Hypertrophy—The Atrophic or Regressive Tonsil—The Anatomy and Histology of the Lingual Tonsil—The Anatomy and Histology of the Pharyngeal Tonsil—The Lymphoid Tissue of the Posterior Wall and Lateral Folds of the Pharynx.

CHAPTER IV. PAGE

THE FUNCTION OF THE TONSILS 55–62

The Hæmopoietic Theory—The Internal Secretion Theory—The Protection Theory—The Eliminating Theory—The Immunity Theory.

CHAPTER V.

THE GENERAL PATHOLOGY AND BACTERIOLOGY OF THE TONSILS.—THEIR RELATION TO SYSTEMIC INFECTIONS 63–77

The Bacteriology of the Crypts—The Relation of the Tonsils to Systemic Infections—The Relation of Age to Tonsillar Infection.

CHAPTER VI.

DISEASES OF THE TONSILS 78–114

Acute Tonsillitis—Acute Follicular Tonsillitis—Septic Sore Throat—Acute Suppurative Tonsillitis—Peritonsillar Abscess (Quinsy Sore Throat)—Vincent's Angina—Chronic Tonsillitis—Chronic Suppurative Tonsillitis—Cyst of the Tonsil—Calculus of the Tonsil—Hyperkeratosis Tonsillaris—Diphtheria—Tuberculosis of the Tonsils—Syphilis of the Tonsils—Diseases of the Lingual Tonsil—Hypertrophy—Acute Lingual Tonsillitis—Chronic Retention—Abscess Formation—An Accessory Thyroid Gland.

CHAPTER VII.

DISEASES OF THE PHARYNGEAL TONSIL (ADENOIDS) 115–123

Thornwaldt's Disease.

CHAPTER VIII.

NEOPLASMS OF THE TONSILS 124–127

Benign Neoplasms—Malignant Neoplasms.

CHAPTER IX.

SURGERY OF THE TONSILS 128–147

The Choice of Operations—Tonsillotomy—Indication — Technique — Tonsillectomy — Indications —

PAGE

Anesthesia—The Preparation of the Patient—The Position of the Patient—The Operations—Treatment of the Operative Wound—Post-Operative Treatment.

CHAPTER X.

COMPLICATIONS AND SEQUELÆ OF OPERATIONS ON THE TONSILS 148–160

Hemorrhage—Septic Infection—Post-Operative Diphtheria—Diphtheria Carriers—Post-Operative Deformities—The Effects of Tonsillectomy on the Singing Voice.

ILLUSTRATIONS.

CROSS-SECTION OF HUMAN TONSIL . . . . . *Frontispiece*

FIG.		FACING PAGE
1.	Section of the faucial tonsil	18
2.	Section of lymphoid tissue of the tonsil	20
3.	Faucial tonsil, human embryo of seven months, showing the crypts in different stages of development . . .	22
4.	Faucial tonsil, human embryo of seven months, showing the formation of a branching crypt	22
5.	Diagrams illustrating the development of the tonsil . .	24
6.	Tonsil of childhood. The relation of the capsule to the plica triangularis	30
7.	Tonsil of childhood. The development of the attached plica	32
8.	Tonsil of childhood. The relation of the capsule to the supratonsillar fossa	34
9.	Diagram showing the upper cervical lymphatic glands .	36
10.	Cross-section of the human tonsil of six months . . .	38
11.	Cross-section of the human tonsil of eleven months . .	40
12.	Small field from Fig. 10, showing the follicles distinctly .	42
13.	Field from Fig. 10, showing two crypts	44
14.	Cryptic epithelium of the tonsil of the child under high magnification	44
15.	Hypertrophy of the tonsil of the child	46
16.	Fibrous hypertrophy of the adult tonsil	46
17.	The atrophic tonsil (twenty years)	48
18.	The regressive tonsil of the adult (fifty-three years) .	48

FIG.		FACING PAGE
19.	Vertical section of the lingual tonsil, from a child of twelve years	50
20.	Vertical section of the pharyngeal tonsil (eleven years)	50
21.	Epithelium of a crypt of the pharyngeal tonsil	52
22.	The organisms of Vincent's angina	92
23.	Hyperkeratosis of the tonsil	102
24.	Hyperkeratosis of the tonsil, showing the compact character of the cryptic epithelium	102
25.	Latent tuberculosis of the tonsil	104
26.	Field from Fig. 24, showing the histology of the tubercle	106
27.	Active tuberculosis of the tonsil, showing the tubercle bacilli	106
28.	The La Force adenotome, the Schuetz adenotome and the Boeckmann curette	122
29.	The right-angle tonsil knife, the author's tonsil grasping forceps and the peritonsillar knife for tonsil dissection	136
30.	The dissection of the tonsil. First step	138
31.	The dissection of the tonsil. Second step	138
32.	The dissection of the tonsil. Third and fourth steps	140
33.	The dissection of the tonsil. The sinus tonsillaris after the tonsil has been removed	140
34.	The Sluder Guillotine (Sauer's modification)	142
35.	Schoemaker's artery forceps	152
36.	Diagrams showing the correct and incorrect position of sutures	152
37.	Mosher's Aneurism Needle and Suture Carrier for suturing the faucial pillars	152
38.	Suturing the faucial pillars	154
39.	Michel's metal clamps for the control of tonsillar hemorrhage being placed in position	154

THE TONSILS.

CHAPTER I.

THE GENERAL NATURE OF LYMPHOID TISSUE.

Before describing the anatomy of the tonsil in detail, it will be well to explain briefly the general character of lymphoid tissue, of which it is composed. Lymphoid tissue in its simplest form may be defined as a reticular connective tissue with a greater or less number of lymphocytes in its mesh. The lymphocytes cannot be distinguished from those of the blood. They may be scattered diffusely in the reticulum or they may be closely packed within a circumscribed area, and we have accordingly diffuse lymphoid tissue and circumscribed lymphoid tissue. As there is no sharp distinction between the two, I shall in the following pages apply the term *diffuse lymphoid tissue* to both indiscriminately, meaning by that, lymphoid tissue with an indefinitely disposed reticulum, in contradistinction to the *lymphoid follicle,* in which the reticulum assumes a definite form.

Lymphoid tissue is widely distributed in the body. It is found in the lymphatic glands, in the Malpighian corpuscles of the spleen, and in the mucous membranes of the alimentary and respiratory tracts, where it occurs both in the widely diffuse form and in the form of nodules, the most prominent of which are the solitary follicles and Peyer's patches of the intestinal mucosa, and the tonsillar ring of the fauces and pharynx. The mucosa of the

vermiform appendix contains a large number of lymphoid follicles.

If a slide containing a cross-section of one of the lymphoid nodules of the pharynx, stained with eosine and methylene blue, is held to the light, it shows an almost uniformly stained light blue surface. In close relation to the epithelium, and at more or less regular intervals, are round or oval areas just large enough to be seen without the aid of a glass, which are differentiated from the surrounding tissue. Each shows a circle of deep blue which is usually considerably thickened on the side nearest the epithelium, giving a seal ring effect, while within the circle is a center of a pale rose color. These are the lymphoid follicles. Examined under the low power of the microscope, the general surface shows a fine and indefinitely arranged reticulum, packed with lymphocytes and partially obscured by them. Other cells are present but are comparatively inconspicuous. The blue ring at the periphery of the follicle shows a reticulum arranged in definite concentric circles round the pale center; its mesh is even more crowded with lymphocytes than the adjacent diffuse tissue. The center shows an extremely delicate and indefinite reticulum with a loose aggregation of cells which take the nuclear stain but faintly or are acidophylic in character. Examined under the high power the cells of the center appear at first glance to be of many different kinds. On closer examination, however, it will be seen that there are but two types of cells. The more numerous are cells larger than the lymphocyte, with faintly stained nucleus and indefinite cell outline. The nuclei often show mitotic figures. These cells are the lymphoblasts or "mother cells." Between them and the lymphocyte many intermediate forms are found in the centers, the lymphocytes becoming more predominant as the periphery is approached. The second type of cell in the

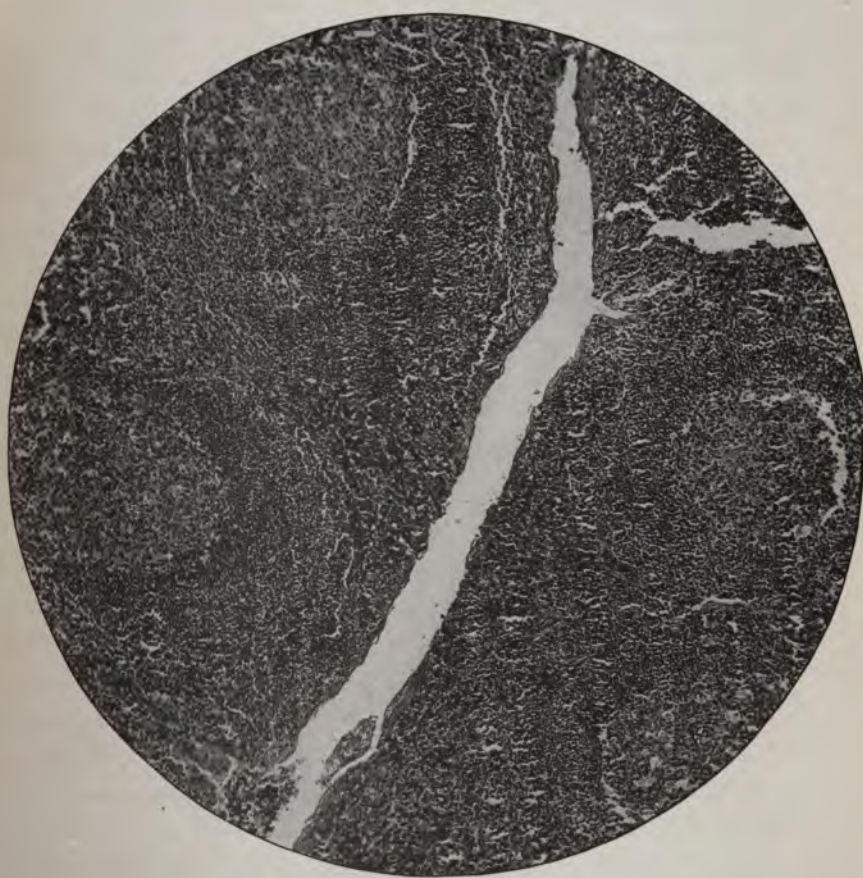

Fig. 1.

Section of the faucial tonsil. Two follicles are seen in the diffuse lymphoid tissue on either side of the crypt.

centers has an acidophylic protoplasm and a large, pale, vesicular nucleus. This is the endothelial cell of the reticulum. It is very phagocytic and often shows nuclear fragments in its protoplasm. Both the lymphoblasts and the endothelial cells are found in the diffuse tissue outside of the follicles, but their numbers are comparatively small and they are masked by the large numbers of lymphocytes. Polymorphonuclear leucocytes are present in small numbers in the diffuse tissue, their proportion increasing somewhat near the epithelial surface. Plasma cells [1] are found in considerable numbers immediately below the cryptic epithelium, in the vicinity of the fibrous framework of the node and around the blood vessels.

In the mucous membranes the lymphoid tissue is developed in the fibrous layer (the tunica propria). It may be diffuse, in which case it is microscopic in character; or a single follicle may appear, usually embedded in a small amount of diffuse tissue (the solitary follicles of the intestinal mucosa). Several closely related follicles with diffuse tissue between them, form a patch of considerable size, (Peyer's patches). The area of such a patch is limited only by the number of associated follicles; but as the follicles are not superimposed but simply lie side by side, it will be seen that the thickness of a nodule in a simple mucosa is limited to the thickness of a single follicle plus a slight amount of diffuse tissue. Whenever, therefore, lymphoid nodules of any considerable bulk are developed in the mucous membranes within a small area, the mucosa will be found to be folded or invaginated in the form of pits or crypts, thus creating a large surface of mucosa within a contracted space, much as the radiating surface of a heating apparatus is increased many times by the use of pipes in

1 These cells are modified lymphocytes with excentric nucleus and an increase in cytoplasm, which is basophylic in character. They may be multinuclear. They are characteristic of chronic inflammatory lesions.

the place of a single large chamber. In this way large masses of lymphoid tissue are developed in the mucous membranes within small areas. Their size depends on the number and size of the folds or crypts of the mucosa. Their unit is the crypt, surrounded by a shallow layer of lymphoid tissue developed in the more superficial layers of the propria, which in turn is enveloped by the deeper fibers of the propria. The small nodules on the posterior pharyngeal wall usually consist of a single unit and the crypt is very small and shallow. The larger of these, however, may be composed of several units. The faucial tonsil is the result of the fusing of many units and the crypts are very extensive and complicated. The lingual and pharyngeal tonsils result from a combination of folding and pitting. In the former the folding is not deep; in the latter it is very extensive.

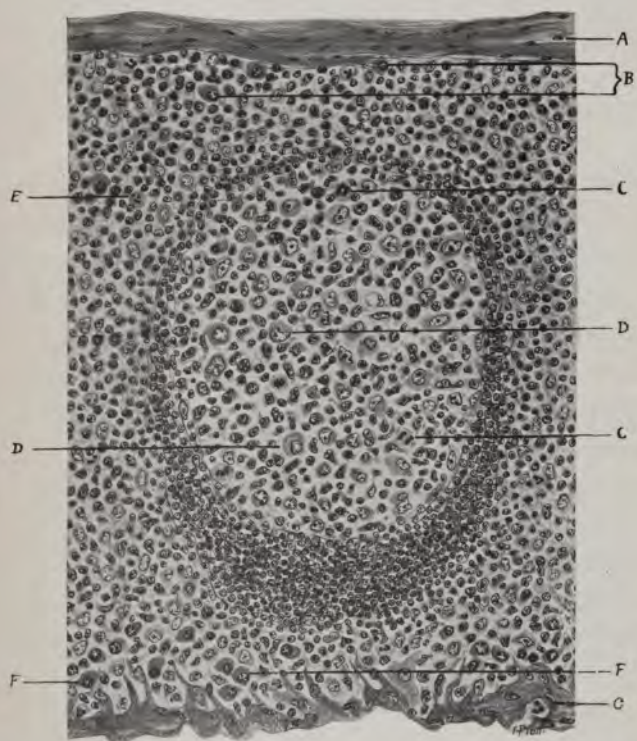

Fig. 2.

Section of lymphoid tissue of the tonsil. High power. The darkly shaded oval ring of lymphocytes with the lighter center (the germinal center) occupying the greater part of the section is the follicle, around which is the diffuse lymphoid tissue. A, fibrous trabecula; B, plasma cells near the trabecula; C, lymphoblasts with mitotic figures of the nuclei; D, endothelial cells of the reticulum; E, polynuclear leucocyte; F, plasma cells near the epithelium; G, epithelium of the crypt in the usual fragmented state of this tissue during childhood.

CHAPTER II.

THE DEVELOPMENT OF THE TONSIL.

The tonsil is developed in a primary tonsillar fossa, the *sinus tonsillaris* (His), which is formed by the dorsal elongation of the second pharyngeal pouch, and becomes sharply marked at the beginning of the third month of fœtal life by the development of the palatal arches. At this time the sinus is narrowed by a small elevation, the *tonsillar tubercle* (Hammar),[1] which lies posterior to the anterior arch. The tubercle soon flattens and becomes undermined posteriorly, so as to form a thin fold, the *plica triangularis* (His), which extends backward from the faucial surface of the anterior arch without line of demarcation between the two, and converts the sinus into a pocket of which it forms an incomplete inner wall. The plica is attached above to the superior part of the posterior arch, anteriorly to the anterior arch, and below to the pharyngeal wall just above the base of the tongue. Between the free posterior border of the plica and the posterior arch is a narrow opening which connects the sinus with the faucial cavity. The sinus is in shape a right angle triangle, owing to the fact that the posterior arch extends nearly horizontally backward. It retains this shape until some time after birth, when the posterior arch is gradually drawn into a nearly vertical position by the forward growth of the tongue. As late as the end of the second year it may still have a decided backward inclination.[2]

1 Hammar, J. A.: Studien über die Entwicklung des Vorderdarms, etc. Archiv für mikr. Anat., Vol. lxi, 1903.

2 Mosher, H. P.: The Tonsil at Birth. Laryngoscope, Nov., 1903.

At about the middle of the third month another fold appears, the *intratonsillar fold* (Hammar), which springs from the outer wall of the sinus and extends from about the middle of the plica upward and backward to the posterior arch. It divides the sinus into two fossæ, a superior and an inferior, which become the points of development of separate tonsillar lobes. Of these fossæ the superior is the larger and deeper. It is bounded on all sides sharply; above and in front by the plica, which converts it into a deep pocket, behind by the posterior arch, and below by the intratonsillar fold. The inferior fossa is shallow and is sharply marked only in front and below, where the plica forms a pocket of varying extent. Elsewhere its lateral wall merges insensibly with the lateral pharyngeal wall. In the later months of fœtal life the posterior border of both fossæ may become more sharply marked by the development of another fold, the *plica retrotonsillaris,* which extends forward from the anterior edge of the posterior arch. It is continuous above and below with the plica triangularis, so that the combined folds extend completely round the sinus. This fold is inconstant.

The Development of the Crypts.—At the end of the fourth month of fœtal life there begin to be developed in the floor and outer wall of each fossa solid epithelial sprouts which grow outward into the surrounding fibrous tissue of the mucosa. They differ in shape and size, some being round or oval and without marked change in their contour throughout their length. Others present branched protuberances of various length and size. These solid sprouts do not all appear at once, but, according to Stöhr,[1] are developed from time to time, not only during fœtal life but throughout the first year of infancy. I have found them in the tonsils of

1 Stöhr, P.: Die Entwicklung des adenoiden Gewebes, usw., Festschr. z. fünfzigyährigen Doktar jubilaum von Nägeli und Kölliker, 1891. (Author's abstract in Anat. Anz., Vol. vi, 1891–1892.)

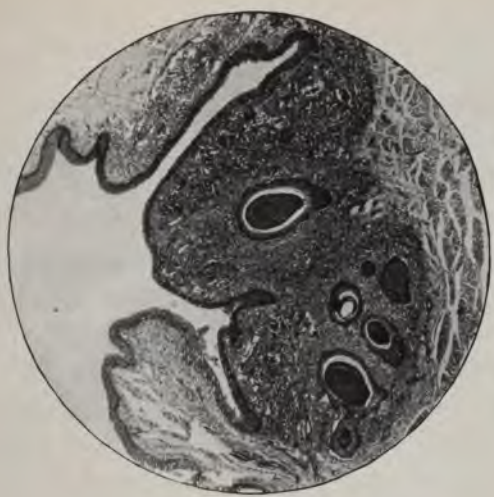

Fig. 3.

Faucial tonsil, human embryo of seven months, showing the crypts in different stages of development. The plica triangularis is in the lower left quadrant.

Fig. 4.

Faucial tonsil, human embryo of seven months, showing the formation of a branching crypt.

infants up to the eleventh month. Soon after their appearance they become hollow through the degeneration of their central cells, which form loose horny plugs and are gradually expelled into the faucial cavity. The result is a series of blind epithelial pits, which at first are quite open, retaining the contour of the original solid buds. With the development of the lymphoid tissue around them their walls become compressed, so that they assume more and more the aspect of epithelial slits as we find them in the mature tonsil.

The Lymphoid Tissue.—Around these epithelial outgrowths lymphoid tissue is developed in the more superficial fibers of the tunica propria of the mucosa. It is at first of the diffuse variety, and, according to Stöhr, remains so until about the fourth month of infancy. Hammar, however, found secondary nodules (follicles), in the later months of fœtal life (embryo of 245 mm.), and Grünwald [1] reports finding them in embryos of 7 and 8 months. I found none in the tonsils of three fœtuses of 7, 7 and 8 months respectively which were sectioned serially; and in five infant tonsils of 6, 7, 9, 10 and 11 months, follicles were plainly marked only in the last three. In the first two only faint suggestions of follicles could be seen.

The Root of the Tonsil.—That part of the surface of the outer wall of the sinus which is concerned in the development of the epithelial buds constitutes the root or point of attachment of the tonsil to the pharyngeal wall. It varies in extent, and this variation has an important bearing on the character of the fully developed tonsil and also on the depth of the fossæ which surround it. This will be discussed in the section on anatomy and histology.

With the increase in the number of epithelial buds and in the lymphoid tissue around them, the two tonsillar lobes

1 Grünwald, L.: Ein Beitrag zur Entstehung und Bedeutung der Gaumenmandeln. Anat. Anz., Vol. xxxvii, 1910.

EXPLANATION TO FIG. 5.

DIAGRAMS ILLUSTRATING THE DEVELOPMENT OF THE TONSIL.

(See opposite page.)

The left-hand figure in each row represents the sinus tonsillaris at the fourth month of fœtal life before the appearance of tonsillar tissue. The succeeding figures show the gradual development of the tonsil and explain the relationship which it assumes to the surrounding tissues. The upper four figures are in cross-section and show the development of the tonsil with a free plica. The middle row, also in cross-section, shows the development of the attached plica. The lower row, in longitudinal section, shows the development of the tonsil and the formation of the supratonsillar fossa.

A. Sinus tonsillaris.
B. Faucial epithelium.
C. Fibrous mucosa.
D. Muscle fibers of anterior pillar.
E. Posterior pillar.
F. Plica triangularis.
H. Superior constrictor of the pharynx.
K. Epithelial bud—the anlage of the crypt.
L. Fibrous trabecula springing from M—the capsule.
N. Anterior fossa.
P. Posterior fossa.
R. Crypt in the plica.
S. Muscle fibers of the palate.
T. Supratonsillar fossa.

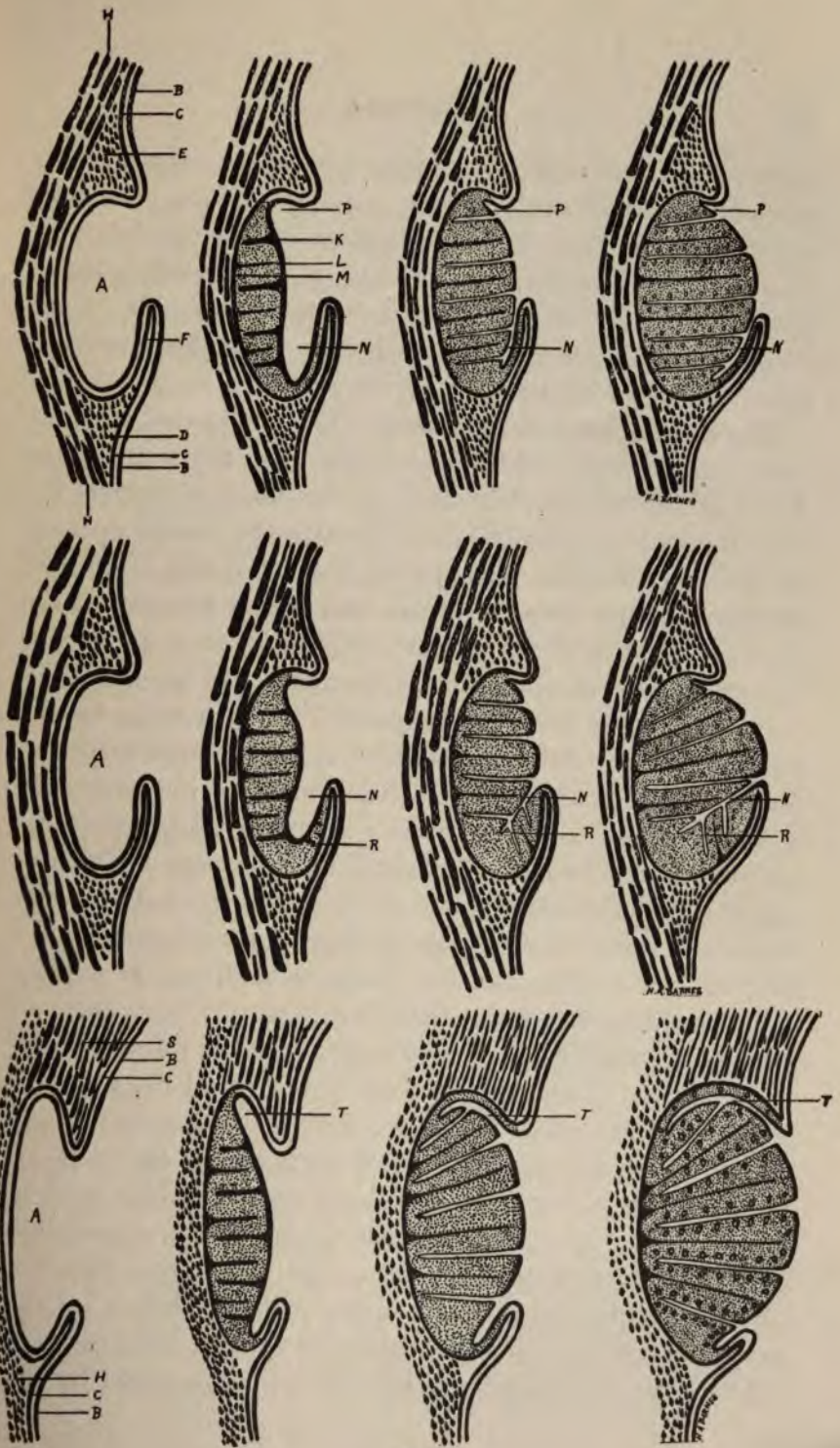

Fig. 5.

LANE LIBRARY. STANFORD UNIVERSITY

expand and eventually fuse at the line of the intratonsillar fold, which disappears as such, leaving either a crescentic epithelial cleft of varying depth between the two lobes, or more often only a fibrous trabecula, which extends between the lobes to the fibrous mucosa on the outer side of the tonsil. The line of demarcation between the lobes is usually plainly marked in the fully developed tonsil.

The Development of the Fossæ.—The now united tonsillar mass presses more and more closely upon the walls of the sinus, which surround it much as the calyx surrounds the growing bud. It finally bursts through the faucial opening of the sinus; and the plica, partly because it may be pushed forward by the growing tonsil, and partly because of the forward growth of the tongue, may undergo a greater or less reduction at its inferior insertion. If no reduction takes place, the tonsil is suspended as by a sling by the plica and a deep fossa exists between the two anteriorly and inferiorly. Between this condition and one in which only a slight fringe of plica remains anteriorly, all gradations may be seen. In the latter condition the inferior fossa is wanting and the inferior lobe of the tonsil lies naked in the fauces, in close relation with the base of the tongue and the lingual tonsil. The anterior fossa is shallow. If a plica retrotonsillaris is present there is a posterior fossa between it and the tonsil, which is continuous with the inferior fossa if one exist. The superior lobe of the tonsil expands upward into the cul-de-sac which forms the superior angle of the sinus, the walls of which surround it like a hood. Between the two an extensive fossa remains which may be quite open or its epithelial surfaces may be in apposition. This is the *supratonsillar fossa.* Its size varies with the size of the original pocket and also with the height on the outer wall of the sinus to which the root of the tonsil extends. Its faucial opening is more or less covered by the

upper part of the plica, so that internally it is continuous with the anterior fossa, and, if one exist, with the posterior fossa. The ventral walls of the sinus surrounding the tonsil have a small amount of lymphoid tissue developed in them, sometimes with shallow cryptic formation. This is especially true of the walls of the supratonsillar fossa and of the plica anteriorly. This lymphoid tissue is continuous at the tonsillar root with that of the main bud, and must be considered as forming a part of the same. At times the amount of lymphoid tissue developed in the deeper layer of the plica is so great as to form a thick wedge-shaped mass which is continuous with the main bud of the tonsil at its base. Under these conditions the plica has the appearance of being directly attached to the tonsil and the anterior fossa is converted into a deep vertical crypt. This is the so-called *attached plica.* (Fetterolf.)

The Development of the Capsule.—The lymphoid tissue of the tonsil is developed entirely within the more superficial fibers of the tunica propria of the mucosa. The deeper layers of the propria are pushed aside by this development and condensation takes place in them, so that they form a thin, compact membrane, the capsule, surrounding the lymphoid mass on all sides not covered by epithelium. It is directly continuous with the propria of the surrounding mucosa. The fibrous trabeculæ, which extend from the inner side of the capsule into the lymphoid tissue, have the same derivation as the capsule. Theoretically the individual units of the tonsil, each composed of a crypt with its surrounding lymphoid tissue, are separated from each other laterally by the fibrous mucosa, and there are as many trabeculæ as there are crypts, the fibrous fingers on the one side being dovetailed with those of epithelium on the other. The majority of these trabeculæ are, however, completely infiltrated with lymphocytes, their

fibers making up the fine reticulum of the diffuse lymphoid tissue. A few remain well marked, two or three being the usual number seen in a longitudinal section.

Histogenesis of the Tonsil.—The origin of the lymphocytes of the tonsil as well as of other lymphoid organs, is a question upon which observers are not agreed. They are, however, probably of mesodermal origin (Stöhr, Hammer, Kollman, Grünwald); but whether they migrate from the blood vessels into the connective tissue (Stöhr), or are derived from the fixed cells of the mesoderm (Hammer), is not known. Retterer's [1] theory that they are derived from metaplasia of the epithelial cells of the tonsillar buds, seems untenable. It owes its conception to the supposed epithelial origin of the small cells of the thymus, and to the well known changes which take place in the cryptic epithelium of the tonsil. Neither the origin nor the character of the small thymus cells have, however, as yet been definitely determined; and the lymphoid tissue of the tonsil often becomes well developed, even with follicle formation with germinal centers, before any marked degeneration of the epithelium takes place.

1 Histogenèse du Tissu Réticulé aux dépens de l'Epithelium, Anat. Anz., Bd. 13, 1897.

CHAPTER III.

THE ANATOMY AND HISTOLOGY OF THE TONSILS.

The Anatomy and Histology of the Faucial Tonsil.

The faucial tonsil is a globular mass of lymphoid tissue lying, one on either side of the fauces, in a recess (the sinus tonsillaris), which is formed by the palatal arches. It is the largest of the lymphoid nodules of the respiratory and alimentary tracts, and differs from other such nodules only in its size, its compactness, and in the extent and complexity of its crypts. It may be nearly spherical in shape, though it is usually much greater in its longitudinal than in its antero-posterior diameter, and is somewhat compressed from within outward. It has an internal and external surface, an anterior and a posterior border, and a superior and an inferior pole. It is originally developed in two lobes, a lower and an upper, which become fused shortly before birth. Their line of demarcation may often be seen after the full development of the organ. It is attached to the walls of the sinus by a root which includes a variable portion of its outer surface and of its anterior and posterior borders. This attached surface is covered by a fibrous membrane, the capsule, which is continuous with the fibrous mucosa of the surrounding mucous membrane. From its inner surface there extends a series of fibrous trabeculæ which divide the tonsil into lobes. All other surfaces of the tonsil are covered by epithelium. It presents on its epithelial surface the openings of from ten to twenty pits

or crypts, which extend deeply into its substance practically as far as the capsule.

The Crypts may be single and without noticeable change in calibre throughout their length; or they may be extensively branched and their calibre much greater below the surface than their faucial openings would indicate. Their walls are normally in apposition; yet the accumulation of cellular debris within them is so frequent that a mild degree of the irregular pocketing that results, cannot be considered abnormal. The crypts extend in a general outward direction; those that empty into the supratonsillar fossa extend downward and outward. These latter drain poorly both on account of their direction and because of the closed condition of the fossa. The same is also true of the crypts that empty behind the plica triangularis.

The Sinus Tonsillaris, the walls of which surround the tonsil on all but its inner side, is a triangular depression bounded anteriorly by the anterior faucial pillar (palato-glossus muscle), posteriorly by the posterior faucial pillar (palato-pharyngeus muscle), superiorly by the tissues of the soft palate, and externally by the superior constrictor muscle of the pharynx. It is deep above, where it may end at the apex formed by the junction of the pillars; or it may extend considerably above this point into the tissues of the soft palate, which form a dome-shaped matrix for the superior pole of the tonsil, surrounding it like a hood. It becomes progressively more shallow as the line of the insertions of the pillars is approached, at which point, just above the base of the tongue, it disappears altogether.

The Plicæ.—The anterior and posterior boundaries of the sinus may be augmented internally in varying degree, and an inferior boundary established, by two folds of mucous membrane, the *plica triangularis* and the *plica retrotonsillaris,* which extend from the internal border of the

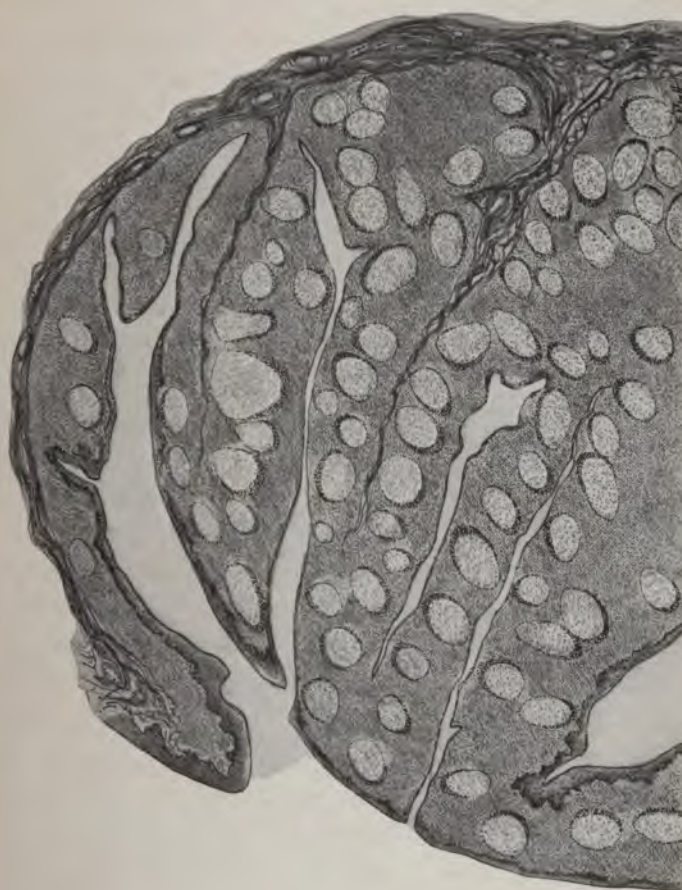

Fig. 6.

Tonsil of childhood. The relation of the capsule to the plica triangularis. The plica is shown at the extreme left of the figure as a thin band of tissue, to the right of which is the anterior fossa. The faucial layers of the plica do not appear in the cut, as they were not removed during the operation. The line of incision is seen near the tip of the plica, extending through its faucial layers to the capsule which bounds the upper and left sides of figure. There is a slight amount of lymphoid tissue developed in the plica.

anterior and posterior pillars respectively. In their original state, and before the bulk of the growing tonsil has filled the sinus, they form an incomplete inner wall to the sinus,—a sort of hymen with longitudinal perforation extending parallel to the posterior pillar. With the growth of the epithelial buds and the deposition of lymphoid tissue around them, the plicæ assume a calyx-like relation to the expanding mass of the tonsil. They are reduplicated folds of mucosa with their fibrous layers in apposition. They, therefore, are composed of four layers, disposed from within outward as follows: faucial epithelium, fibrous mucosa, fibrous mucosa, sinus epithelium. A varying amount of lymphoid tissue, sometimes with shallow cryptic formation, is developed in the third of these layers. It may form a thin, almost microscopic thickening, with sharp line of demarcation between it and the lymphoid tissue of the main bud of the tonsil at its root. It often, however, forms a wedge-shaped mass of tissue whose base is directly continuous at the tonsillar root with the lymphoid tissue of the main mass. The result is an attached plica. (Fetterolf.) (Fig. 7.)

The Plica Triangularis is constant, but varies much in its extent. In its most developed form it is a right-angle-triangular web of folded mucosa with its apex attached to the uppermost part of the inner border of the posterior pillar, its perpendicular attached to the inner border of the anterior pillar, and its base inserted into the lateral pharyngeal wall just above the base of the tongue, along a curved line, corresponding with the line of attachment of the tonsil inferiorly. It covers from above downward a progressively increasing area of the anterior internal surface of the tonsil, encircling its lower pole like a sling. With the forward growth of the tongue the inferior insertion of the plica may undergo a greater or less reduction, so that it may appear only as a very inconspicuous fringe

of mucosa extending slightly beyond the inner border of the anterior pillar over the anterior border of the tonsil. Between these two extremes all gradations may be seen.

The Plica Retrotonsillaris is inconstant. When it exists it is continuous above with the apex of the plica triangularis; and with the same structure below, when the inferior insertion of that fold extends to the posterior pillar. In the latter case the combined folds form a complete ring round the internal border of the sinus.

The Root of the Tonsil.—The sinus tonsillaris is in the beginning a deep cul-de-sac, lined completely with faucial mucosa. With the development of the crypts in the mucosa of its deeper parts and the deposition of lymphoid tissue around them, the epithelium is separated from its fibrous mucosa and expands in all directions except externally, so that the tonsillar mass which it covers, eventually not only fills the sinus but bursts through its faucial opening into the faucial cavity. That portion of the walls of the sinus concerned in this development constitutes the point of attachment, or root of the tonsil. It varies in size, sometimes being confined to the outer wall; often, however, extending internally over the anterior and posterior walls, even to their internal borders. The superior angle of the sinus is never involved in the development of the main lobes of the tonsil, though it usually has a thin layer of lymphoid tissue developed in it which is continuous on all sides, except internally, with the lymphoid tissue of the upper pole. Between the epithelial surfaces of the tonsil and the surfaces of the sinus not covered by the root of the tonsil a series of cul-de-sacs remain. Their depth depends upon the original depth of the sinus, the extent of the plicæ, and the size of the tonsillar root. The superior and anterior of these are of great clinical importance.

The Superior or Supratonsillar Fossa lies between the su-

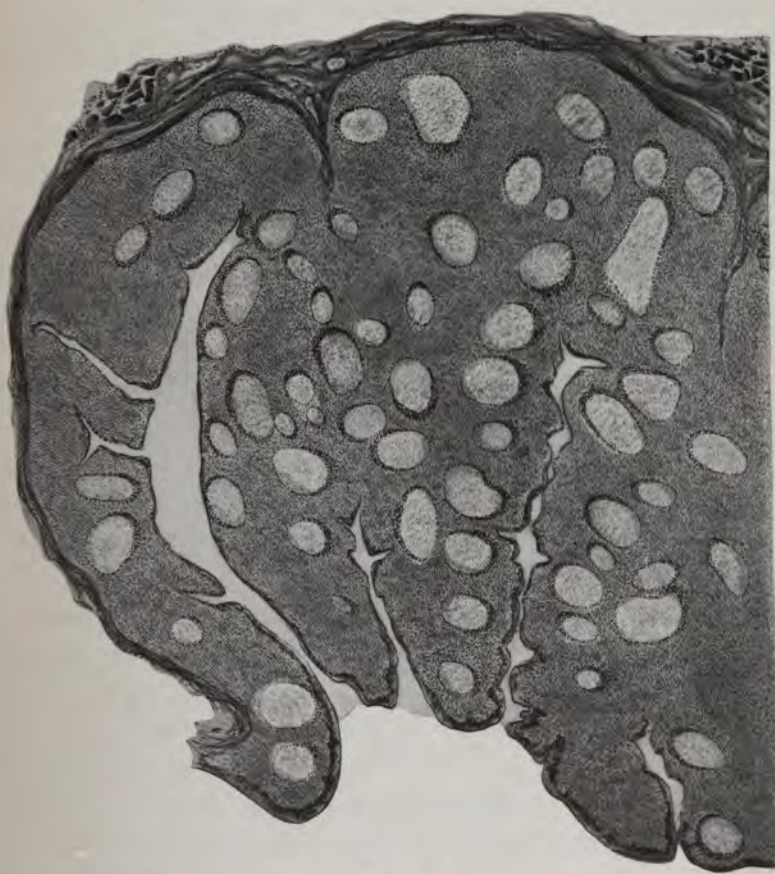

Fig. 7.

Tonsil of childhood. The development of the attached plica. Plica shows at the left side of the figure with a moderate amount of lymphoid tissue developed in it. Both the plica and the anterior fossa may still be recognized as such. More pronounced development of lymphoid tissue in the plica makes its recognition difficult, as it then appears to be a part of the main lobe of the tonsil.

perior pole of the tonsil and the superior angle of the sinus. It is constant. It may be a distinct space, triangular in shape, with its faucial opening more or less completely covered by the upper segment of the plica, which at this point is sometimes called the *plica supratonsillaris.* When the sinus extends high into the palate, the superior lobe of the tonsil pushes its way into this superior cavity and the supratonsillar fossa is reduced to a blind epithelial sac with walls in apposition. It may be very extensive, often admitting a probe as far as the plane of the external surface of the tonsil. A variable amount of lymphoid tissue is developed in its superior wall. (Fig. 8.)

The Anterior Fossa lies between the anterior-internal surface of the tonsil and the anterior pillar and plica triangularis. (Figs. 6 and 7.) Its surfaces are always in apposition. Superiorly it is continuous with the more superficial part of the supratonsillar fossa. In cases of extreme development of the plica it is continued downward and backward round the inferior pole of the tonsil to the posterior pillar.

A Posterior Fossa exists when a plica retrotonsillaris is present, and is continuous above with the more superficial part of the supratonsillar fossa. In cases where all the plicæ are present and in full development the combined fossæ form a complete moat round the tonsil, comparatively shallow everywhere except at the superior angle where the supratonsillar fossa extends over the superior pole of the tonsil to the plane of its outer surface.

The Capsule covers all surfaces of the tonsil not covered by epithelium. Theoretically it includes only that part of the deeper layers of the fibrous mucosa of the sinus that covers the attached surface of the main bud of the tonsil. As the mucosa of the more internal surfaces of the sinus, including the plicæ, have lymphoid nodules developed in

them, often directly continuous at the root of the tonsil wit the lymphoid tissue of the main mass, it seems best t consider the capsule as including the fibrous mucosa of th entire sinus, even to the internal rim of the plicæ. At thi point it is folded upon itself and becomes the propria o the faucial mucosa.

It will be appreciated from the above description tha the tonsil lies in and not under the mucous membrane; tha it is in reality simply a complicated mucous membrane wit lymphoid nodules developed in the more superficial fiber of its tunica propria. If this fact is kept in mind, the re lations of its various parts to each other and to the sur rounding tissues are easily understood.

Types of Tonsil.—Two distinct types of tonsil exist, th pedunculated and the buried. The *pedunculated tonsil* i nearly spherical in shape, is attached by a small base t a shallow sinus and appears prominently in the fauce the walls of the sinus hiding little but its external surfac Because of its extreme prominence it is usually called hy pertrophied, yet it may not be excessive in size, the averag being much smaller than in the buried type. The *buried tonsil* has a broad base attached to a deep sinus. The cul de-sac at the superior angle is especially marked and th superior lobe of the tonsil is firmly held in place and al most completely hidden by its walls. The tonsil may no appear internally beyond the plane of the pillars. Thi type of tonsil may be very large without giving any indi cation of it to the casual observer. It is only when it i pulled inward with a tenaculum or is thrown inward b the muscles of the palate during gagging, that its size ma be appreciated. The buried tonsil, however, often extend internally far beyond the pillars, showing as prominentl in the fauces as the pedunculated tonsil. The largest ton sils are of this type.

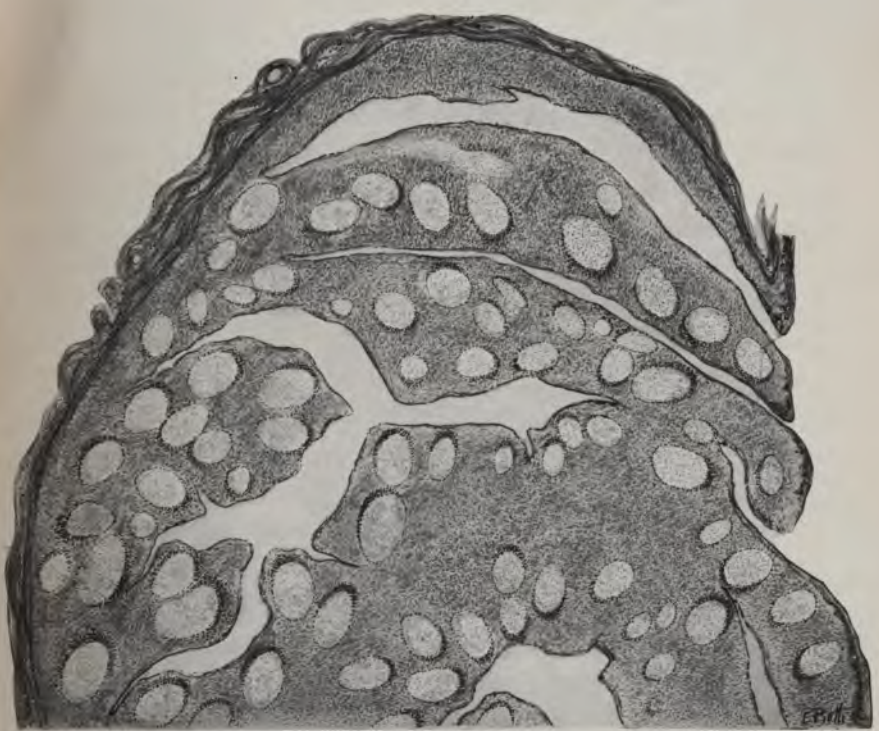

Fig. 8.

Tonsil of childhood. The relation of the capsule to the supratonsillar fossa. (Upper part of figure.) No follicles are present in the superior wall of the fossa, which is often much thickened by shallow cryptic formation and the development of numerous follicles.

The Blood Supply of the Tonsils.—THE ARTERIES.—The tonsil is an extremely vascular organ, receiving its blood supply from the tonsillar and palatine branches of the facial, from the descending palatine branch of the internal maxillary, from the dorsalis linguæ of the lingual and from the ascending pharyngeal. Its chief blood supply is from the tonsillar and ascending palatine branches of the facial. Usually two or three small twigs are given off from the former and one from the latter, though the reverse arrangement may be found. These branches pierce the superior constrictor opposite the lower pole of the tonsil, ascend for a variable distance on the external capsular surface, and enter the tonsil in its lower half. They are the most important arteries of the tonsil from the surgical standpoint as they are the ones most often involved in post-operative bleeding. The descending palatine sends a small branch to the superior lobe which enters its external surface. The dorsalis linguæ supplies the anterior pillar, giving off branches which enter the tonsil along its anterior border, usually in its lower half. Sometimes a branch in the upper segment of the pillar bleeds freely. A branch from the ascending pharyngeal enters the tonsil from the posterior pillar usually in its lower part. The bleeding from the arteries of the pillars is more easily seen and controlled by hemostats and ligature than is the case with those from the facial and ascending palatine which are deep within the lower half of the sinus tonsillaris. I have never seen the superior artery give rise to serious bleeding.

THE VEINS of the tonsil form a plexus lying in the walls of the sinus. According to Fetterolf [1] the largest vessel of the plexus runs down the outer edge of the palato-pharyngeus muscle and joins with veins from the epiglottis and the

1 Fetterolf, G.: The Anatomy and Relations of the Tonsil, etc. Amer. Jour. Med. Sciences, July, 1912.

base of the tongue, forming a large trunk which empties into the pharyngeal plexus. A smaller vein runs down the anterior sinus wall and empties into the lingual veins. The first of these vessels may sometimes be seen after a tonsillectomy, lying superficial in the posterior sinus wall. This vein is of great importance from the operative standpoint, as troublesome bleeding may result if it is cut.

The Lymphatics of the Tonsils.—No *afferent lymphatic stems* have been demonstrated leading to the tonsils. Lénárt [1] has shown by a series of experiments on animals that inert coloring matter injected into the mucosa of the turbinate bodies of the nose, finds its way not only into the tonsil of the same side but even into that of the other side. The amount of coloring matter that entered the tonsil, however, was apparently insignificant compared to the amount found in the upper deep cervical glands. Lénárt's results have recently been corroborated by Henke,[2] who has found colored particles in the tonsils not only after injections in the nasal mucosa but also following injections into the gums. Neither investigator, as it seems to me, has succeeded in proving the existence of definite lymphatic stems from this wide field to the tonsils. Fraenkel [3] has called attention to the frequency with which acute infections in the nose are followed by tonsillitis; and Wright [4] and others claim that the tonsils regularly enlarge during the periods of dentition. The phenomenon in both instances is ascribed to a lymphatic connection between the tonsil and the primary source of irritation. While this may not definitely be

1 Lénárt, Z.: Experimentelle Studie über den Zusammenhang des Lymphgefäss-systems der Nasenhöhle und der Tonsillen. Archiv f. Laryngologie, bd. xxi, 1909.

2 Henke, F.: Die Physiologische Bedeutung der Tonsillen. Archiv für Laryngologie, bd. xxviii, 1914.

3 Fraenkel, B.: Die Infektiöse Natur der Tonsillitis lacunaris. Archiv f. Laryngologie, bd. iv.

4 Wright, G. H.: A Functional Relation of the Tonsils to the Teeth. Boston Med. and Surg. Jour., May 20, 1909.

Fig. 9.

Diagram showing the upper cervical lymphatic glands. The tonsil gland is shown in its normal position, just under the anterior edge of the sterno-mastoid muscle. Directly in front of it, under the angle of the jaw, is the posterior submaxillary gland. Notice that no lymphatics lead from the deep glands under the sterno-mastoid to the tonsil gland.

denied, it may be said that anatomical proof of the assertion is as yet wanting.

The *efferent lymphatics* of the tonsil pass through the fibrous trabeculæ and the capsule, pierce the superior constrictor muscle of the pharynx and empty into the tonsillar gland (Wood), one of the superior deep cervical nodes lying under the anterior border of the sterno-cleido-mastoid muscle, in the angle between the internal jugular and facial veins. It is one of the most constant in position of all the cervical nodes. When enlarged it projects anteriorly beyond the anterior border of the sterno-mastoid and appears superficially from one-half to three-quarters of an inch below the angle of the jaw. As cases of cervical adenitis are so often sent to us with the question, "Is the tonsil the source of the infection?" and as the tonsillar gland or the glands in its immediate vicinity receive their afferents from so many different parts, lesions of which may give rise to adenitis easily confounded with that due to infection through the tonsil, a brief description of the deep cervical glands will be given here.

The deep cervical nodes are divided into a superior and an inferior group. The superior nodes, ten to sixteen in number, extend along the course of the internal jugular vein from the tip of the mastoid to the level at which the vein is crossed by the omo-hyoid muscle. From the clinical standpoint they may be divided into an anterior and a posterior group. The posterior glands lie deep under the sterno-mastoid or along its posterior border. They receive their afferents from the superficial nodes in the suboccipital and mastoid regions, from the retro-pharyngeal glands, and also directly from the mucosa of the pharynx and naso-pharynx and the nasal mucosa posteriorly, including that of the sinuses. When enlarged they are difficult to feel as discrete nodes but form an indefinite swelling under the

sterno-mastoid. Any infection in the wide field from which their afferents are derived may cause their enlargement. Pediculosis and lesions of the lateral and posterior pharyngeal nodules are frequently overlooked in this connection. Their enlargement without involvement of the anterior glands cannot be attributed to the tonsil. The anterior glands form a chain lying just under the anterior border of the sterno-mastoid. They receive their afferents from the tonsil and the base of the tongue and from the submaxillary and submental nodes. Stems from the body of the tongue also pass directly to one of the anterior glands which lies somewhat below the tonsillar gland.

The most posterior of the submaxillary glands is commonly confounded with the tonsillar gland. It is situated just under and anterior to the angle of the jaw. It is never enlarged from infection through the tonsil. One of the most common causes of its enlargement, beyond perfectly obvious lesions of the gums, tongue or cheeks, and one that is frequently overlooked, is an abscess round an old tooth root. An X-ray plate may be necessary to demonstrate this. If the tonsillar gland enlarges alone and there is no lesion at the base of the tongue, the enlargement may be attributed to infection through the tonsil. If the submaxillary glands are involved at the same time, the source of the infection should be looked for anteriorly. Cases in which the posterior cervical glands are involved coincidently with the tonsillar gland are difficult to decide. If it is possible for a gland to be infected through its efferent lymphatics, the tonsils might be the cause of enlargement of the posterior group. In most of these cases, however, the infection is undoubtedly of double origin, the lateral and posterior pharyngeal nodules or the adenoid tissue of the vault being responsible for the posterior enlargement.

The inferior group of the cervical lymph nodes receive

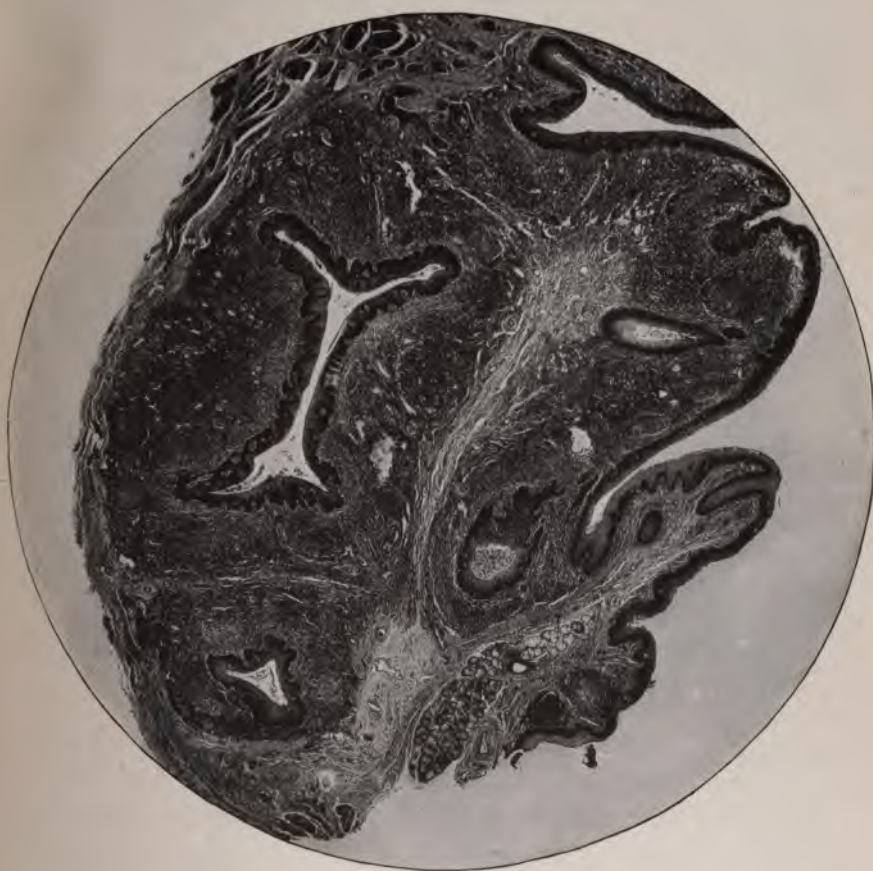

Fig. 10.

Cross-section of the human tonsil of six months. The lymphoid tissue is diffuse, only slight suggestions of follicles being present near the crypt in the lower left quadrant. Some of the crypts are still in the developmental stage. All have as yet an intact epithelium.

afferents directly from the upper nodes. They are of importance in connection with the tonsil chiefly because of the possibility of tubercular infection reaching the pulmonary apices via this route. Grober's [1] experiments on animals showed that the supraclavicular glands form the connecting link between the upper deep cervical nodes and the apical pleura and that inflammatory adhesions may extend the infection to the apices themselves. Wood states that the supraclavicular group only rarely receive afferents from the upper cervical glands, the efferents of which gradually converge and form the jugular trunk, which empties into the subclavian vein at its junction with the internal jugular. According to the same authority,[2] tubercular infections may reach the apices either by the supraclavicular route, or occasionally through an inconstant gland of the upper anterior group which is sometimes found in the notch formed by the junction of the internal jugular and subclavian veins, and is very closely placed to the parietal pleura of the pulmonary apex. In view of the frequency with which primary tuberculosis of the tonsils occurs, the existence of this possible line of invasion between them and the lungs assumes a clinical importance. That this mode of pulmonary infection is frequent, however, is doubtful.

The Nerve Supply of the Tonsils.—The nerve supply of the tonsils is derived from the spheno-palatine or Meckel's ganglion through the middle and posterior palatine nerves and from the glosso-pharyngeal. Fibers from these two sources unite to form a plexus around the tonsil (circulus tonsillaris).

The Relations of the Tonsil.—The tonsil is so placed that its posterior-inferior limits are just in front of and above the angle of the jaw. It can never be felt on the outside

1 Grober, J.: Die Tonsillen als Eintrittspforten für Krankheitserreger, besonders für den Tuberkelbazillus. Klin. Jahrbuch, 1905, xiv.

2 Wood, G. B.: The Tonsils and Tuberculosis. Penn. Med. Jour., June, 1912.

except in cases of malignant growth. On the other hand, a sponge held in the sinus after tonsillectomy and pressed backward and downward may easily be grasped with the fingers behind and below the jaw. This is of importance in post-operative bleeding, as the pressure between the sponge on the inside and the fingers on the outside may be brought to bear directly on the posterior inferior angle of the sinus where bleeding is most likely to occur. Inferiorly the tonsil is in relation with the base of the tongue and the lingual tonsil, from which it may be separated by the lower segment of an extensive plica triangularis; otherwise the two lymphoid masses may be directly contiguous. These lingual nodules should not be mistaken for the lower pole of the tonsil and snipped off with a punch after tonsillectomy, as deep wounds in this region are prone to cause protracted venous bleeding. Superiorly the tonsil is in relation with the soft palate, into which it may mound considerably above the junction of the pillars. It never extends high enough to produce pressure on the Eustachian orifices. It may, however, affect the patency of the tubes by interfering with the muscles of the palate, particularly with the tensor palati. Externally the tonsil lies directly on the superior constrictor muscle of the pharynx, to which it is but loosely attached except at its lower pole where its larger vessels enter. Between the two there is a theoretical space, in which abscess formation often takes place (peritonsillar abscess). External to the superior constrictor is the pharyngo-maxillary space. It is filled with fat and areolar tissue continuous with that of the carotid sheath. It is divided into a posterior and an anterior part by the stylo-pharyngeus and stylo-glossus muscles, the first part being in relation with the internal carotid artery and the internal jugular vein, and the second in relation with the tonsil. In rare cases when pus from a peritonsillar abscess

Fig. 11.

Cross-section of the human tonsil of eleven months. Crypts in various stages of development. There are numerous follicles in the lymphoid tissue which has begun to invade the epithelium of many of the crypts.

has entered the anterior space, this barrier forms a further protection to the carotid sheath. A long styloid process occasionally extends into the anterior space, and may even pierce the constrictor and the tonsillar capsule. It may render a tonsillectomy difficult. In many of these cases however, the bone is not of styloid origin, but is a true osteoma. The internal carotid artery lies two cm. (⅘ in.) behind and external to the posterior pillar (Zuckerkandl). Except in cases of anomalous position it is in no danger of being wounded during tonsillectomy, nor in the opening of a peritonsillar abscess anteriorly. If the abscess points behind the posterior pillar, however, great care should be taken. Aneurism of the internal carotid should be thought of in cases of swelling in this region.

The Normal Histology of the Tonsil.

The tonsil is composed of lymphoid tissue supported by a fibrous framework—the capsule and its trabeculæ. Its inner surface is covered by epithelium which is continuous with that which lines the crypts throughout their extent. The epithelium extends outward to the root of the tonsil where it is reflected upon the internal surface of the folds of mucosa which constitute the plicæ. At the free border of these folds it is again sharply reflected so as to cover their faucial surfaces, from which point it is continuous with the epithelium of the general faucial mucosa. The capsule with its trabeculæ on the outer side forms an inverted replica of the epithelium with its cryptic prolongations on the inner side; the two are dovetailed, so to speak, and are separated at any given point only by the development of a thin layer of diffuse lymphoid tissue in which a single row of follicles, more or less regularly disposed, is embedded. The blind ends of the crypts, therefore, are in close relation to the capsule. The two are never in appo-

sition, but the amount of lymphoid tissue between them is so slight that the crypts may be said, for all practical purposes, to extend to the capsule. The trabeculæ are by no means as numerous as the crypts, owing to the fact that many of them are completely taken up by the lymphoid development, so that the diffuse tissue surrounding a crypt may be continuous with that of its immediate neighbors without fibrous demarcation between them.

The general character of the lymphoid tissue has already been described (p. 18).

The Capsule is composed of the deeper layers of the tunica propria of the mucosa of the sinus tonsillaris, separated from its epithelium by the development, in its more superficial layers, of the lymphoid tissue which composes the mass of the tonsil. It covers the root or attached surface of the tonsil, from which it extends into the calyx-like folds of surrounding mucosa, at the inner edge of which it is continuous with the tunica propria of the faucial mucosa. It is somewhat more compact than the propria elsewhere. It is composed of fibrous tissue, with numerous elastic and striated muscle fibers interspersed. The muscle fibers are derived from the superior constrictor of the pharynx and from the palatal muscles. A number of mucous glands are found in the capsule, being especially numerous at the sides opposite the faucial pillars. Blood vessels appear at intervals, the larger of which are seen at the junction of the trabeculæ with the main capsule, from which point they supply the tonsil through the trabeculæ. Bone and cartilage are occasionally found in the capsule. Their presence may make the dissection of the tonsil difficult. The trabeculæ are of the same composition as the capsule, except that muscle fibers are only occasionally found in them, and then only near their junction with the capsule. At this point the trabeculæ are of good size, but become rapidly

Fig. 12.

Small field from Fig. 10, showing the follicles distinctly. The degeneration of the cryptic epithelium is well seen in the two crypts at the right.

attenuated as they approach the epithelial surface where they are lost in the fine reticulum of the lymphoid tissue.

The Crypts may be simple; usually, however, they are extensively and irregularly branched. Their caliber varies at different depths. In a strictly normal tonsil I suppose the epithelial surfaces of the crypts should lie in apposition throughout their whole course. I have yet to examine such a tonsil. The nearest approach to this ideal that I have found is one in which the inequalities are not sufficient to cause any considerable accumulation of detritus in the crypt. In the great majority of tonsils that are removed, either on account of their size or for the relief of constitutional disturbances, marked pocketing of the crypts is found. These pockets may occur at any point. They are quite as apt to be deep as superficial. They are often found in close relation with the capsule, where they are formed at the blind end of the crypts.

The Epithelium.—The *surface epithelium* is of the stratified squamous variety. It is compact, many layers in thickness, and has a perfectly definite basal outline indented by numerous papillæ. The *cryptic epithelium* is at first similar to that of the surface but becomes greatly modified with the increased activity of the lymphoid tissues during the first year of life. At birth the lymphoid tissue of the tonsil is small in amount and not specially active. Follicles are usually not present. A few lymphocytes may be seen wandering through the epithelium, but they in no way affect its integrity. At about the fourth month of infancy the lymphoid follicles with their germinal centers first begin to show distinctly; vast numbers of lymphocytes are produced, and a correspondingly large number of them find their way into the cryptic epithelium and profoundly modify its character. First the basal outline of the epithelium becomes obscured, and it is difficult to tell where the

lymphoid tissue ends and the epithelium begins. Masses of lymphocytes press outward toward the cryptic cavity and separate the lower layers of epithelial cells from each other, so that they appear as more or less isolated epithelial fingers extending from the surface of the crypt into the lymphoid tissue. In places these fingers disappear altogether, being either absorbed by pressure of lymphoid cells or masked by the large numbers of them. The end result of this process is that there remains only a very thin film of intact epithelium, two or three cells in thickness, lining the cavity of the crypt. At times even these are difficult to make out. This action of the lymphoid cells upon the epithelium of the crypts seems to be due not to any inherent power of motion of the lymphocytes, though they possess that power to a limited degree, but purely to the pressure of numbers. The surface epithelium remains practically unaltered by this pressure as it is able to expand outward and is consequently found intact. But the epithelium of the crypt, caught between more or less pressure on all sides, suffers as described above. At just what age this degeneration reaches its maximum it is difficult to say, though after the first year and a half of life it is usually well advanced. Throughout childhood it remains essentially the same. With the diminution in lymphoid activity which usually occurs at about puberty, a partial regeneration of the cryptic epithelium takes place. This will be described in the section on the regressive or atrophic tonsil.

The Hypertrophied Tonsil.

Hypertrophy of the tonsil in children consists primarily in an increase in the cellular activity of the germinal centers of the follicles. Not only are the follicles increased in number and in size, but the relative size of the germinal centers themselves is greater than in the small tonsil and



Fig. 13.

Field from Fig. 10, showing two crypts—one with epithelium intact, the other with extensive epithelial degeneration.

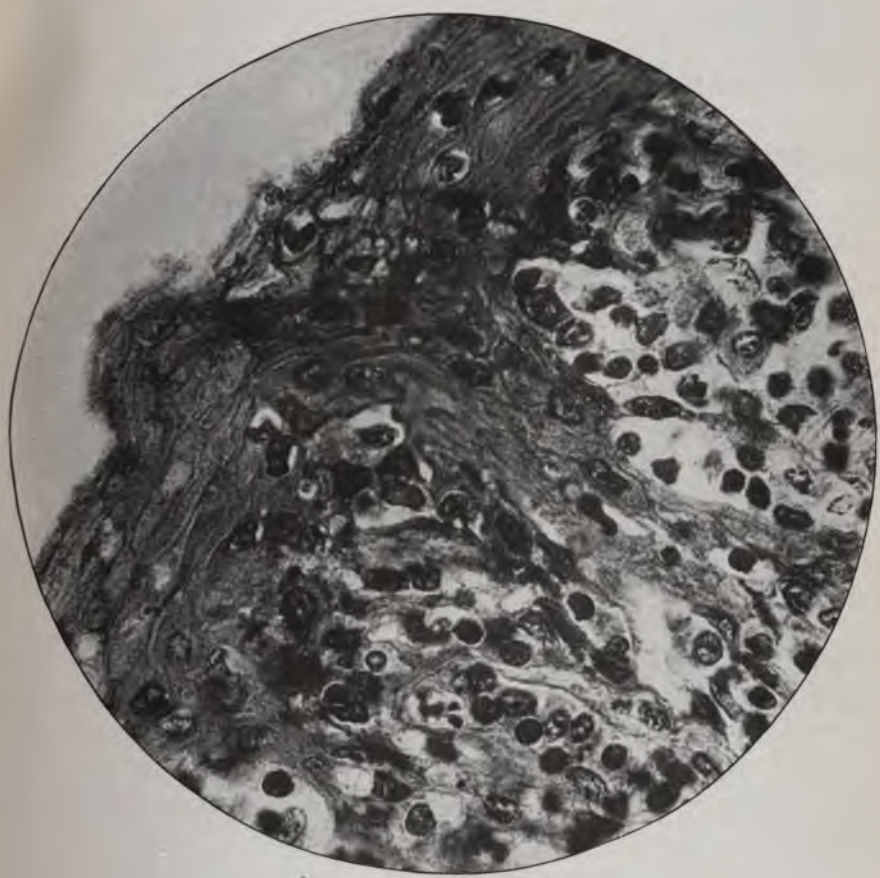

Fig. 14.

Cryptic epithelium of the tonsil of the child under high magnification.

the number of cells undergoing division is increased. Sections of small tonsils usually show the combined area of the follicles to be less than the area of the diffuse tissue. In the hypertrophied tonsil the ratio is reversed and the follicles may become so large as to take up nearly the whole area of a section. The dark ring at the periphery of the individual follicles is reduced to a minimum, nearly the whole follicle being included in the light staining germinal center. The picture is one of great cellular activity. In adults the hypertrophied tonsil does not give the same impression of functional activity. Here the number and size of the follicles may indeed be greater, but the germinal centers are relatively small and show few nuclear figures; or the centers may be absent altogether, the whole follicle being crowded with small lymphocytes and consequently stained a uniform blue. There is usually an increase in the fibrous tissue in these adult tonsils, most marked in the vicinity of the capsule and the trabeculæ. Often these structures are enormously thickened, and the tonsil in every way, except in size, resembles the atrophic tonsil.

What Constitutes Hypertrophy of the Tonsils?—Between the normal tonsil and the hypertrophied tonsil there is no sharp dividing line, either clinically or histologically, the term "hypertrophy" being purely a relative one. The question arises, how large may a tonsil be and yet come within the normal limits of size? Clinically a great deal of confusion has existed regarding this, and I think has been due to the fact that the normal tonsil of childhood is much larger than has commonly been supposed. The so-called buried tonsil which does not protrude beyond the pillars of the fauces has been generally overlooked and considered to be small simply because it appeared to be so to casual inspection; whereas it is nearly always of very considerable size, which may be appreciated if the patient be made to

gag, during which action the constrictor of the pharynx throws the tonsil inward and the palatal muscles become tense over its buried surface so that the outlines of its deeper parts may be seen. On the other hand the tonsil that lies in a shallow sinus and therefore appears prominently in the fauces has usually been pronounced hypertrophied, often when its actual size would not warrant the assertion. Coolidge and Garland[1] have weighed the tonsils from a long series of tonsillectomies in children, done both on account of apparent size and for the usual other reasons for the operation. Their results showed an astonishing uniformity in weight—between forty and fifty grains. Those tonsils that had been pronounced large before operation (the prominent tonsil) were found on the average to be smaller than those whose size had not attracted attention (the buried tonsil); and in many cases in which one tonsil only had been thought to be hypertrophied, the two tonsils were found to be practically of the same weight. We have to recognize that prominence and hypertrophy are not synonymous terms as applied to the tonsils and that their appearance beyond the plane of the faucial pillars is not necessarily an evidence of hypertrophy nor an indication for their removal. Also it may be said that hypertrophy of the tonsil is not *per se* a pathological process but a physiological one. Pathological conditions in the crypts are perhaps more common in large than in small tonsils, owing to the greater depth of the crypts and their consequent greater tendency to retention of cellular debris. This is especially true of the buried tonsil; but unless symptoms are present directly attributable to such conditions or resulting from pressure on neighboring parts, causing obstruction to breathing, thickness of speech or

1 Coolidge, A. and Garland, F. E.: The Removal of Adenoids and Tonsils in Children. Boston Med. and Surg. Jour., Aug. 28, 1913.

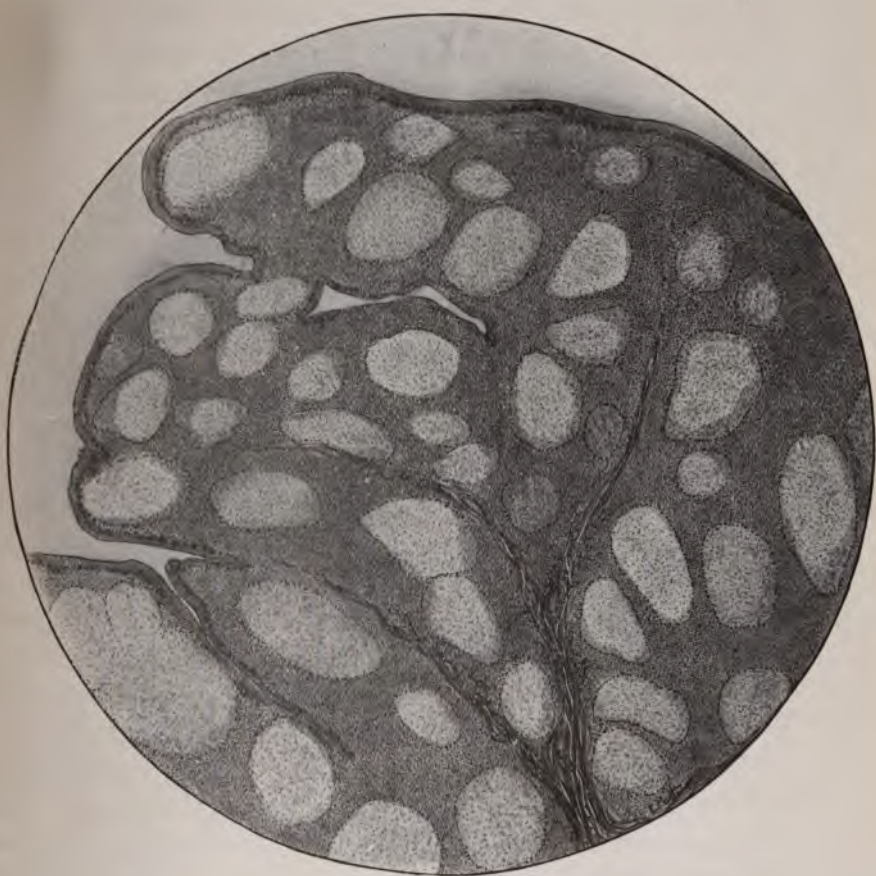

Fig. 15.

Hypertrophy of the tonsil of the child. The follicles are very large—sometimes confluent—and are taken up almost entirely by the germinal centers.



Fig. 16.

Fibrous hypertrophy of the adult tonsil. There is much lymphoid tissue still present, but it is comparatively inactive. The follicles are few and small and their germinal centers either absent or inconspicuous. The fibrous tissue is much increased.

ear symptoms, moderate hypertrophy should not be considered an indication for tonsillectomy. Excessive hypertrophy [1] is easily recognized and usually calls for operative interference, even when symptoms arising from chronic cryptic retention or from absorption are not present.

The Causes of Hypertrophy.—We have no definite knowledge of the causes of hypertrophy of the lymphoid nodules of the fauces and pharynx. It is probable that prolonged irritation of any sort, such as chronic rhinitis, chronic cryptic retention, and recurring acute tonsillitis, has an influence in bringing about this condition. Irritation of irrupting teeth or that due to caries of the teeth, have been claimed as etiological factors. Often no reason can be assigned, all of the nodules of the pharyngeal ring showing a decided tendency to hypertrophy without any of the above conditions being present to explain the phenomenon. Congenital lues is present in many cases, especially in cases of hypertrophy of the adenoid tissue of the vault and posterior pharyngeal wall. They are immensely benefited by appropriate treatment. As regards the influence of acute or chronic rhinitis, it is at times difficult to distinguish between cause and effect and to say whether these supposed causes of hypertrophy are really such or are the direct result of conditions brought about by the hypertrophy itself. Certainly in the case of the pharyngeal tonsil the nasal condition is often secondary to the hypertrophy and disappears or is much benefited by the removal of the adenoid. I have never been able to convince myself of the relation between irrupting or carious teeth and enlargement of the faucial tonsil. Certainly all children are subject to irrupting teeth and nearly all children, at least in the large clinics, have carious teeth. Yet many of those whose

[1] The largest tonsil that I have seen in a child under fourteen years of age weighed 180 grains. In the adult they may be much larger, a weight of 210 grains being the limit in my experience.

mouths are in the worst possible condition have small tonsils; while in many cases of hypertrophy the teeth are in excellent condition. It must also be remembered that no lymphatic connection has ever been demonstrated between the teeth or the surrounding soft parts and the tonsils.

The Atrophic or Regressive Tonsil.

As the hypertrophied tonsil is the direct result of increased cellular activity in the germinal centers of the follicles, so the regressive tonsil is one in which such activity is on the decline. The process is a gradual one, usually beginning shortly before puberty and extending through a variable period of time. Often we find tonsils of eighteen to twenty years in which the changes have been completed and the organs consist of fibrous tissue in which lymphoid tissue is inconspicuous and of the diffuse form without follicles. On the other hand it may extend over many years and never reach its extreme stage, and we find tonsils of forty or fifty years in which the lymphoid tissue is considerable, the follicles numerous, and the fibrous tissue not relatively great. The germinal centers of such tonsils are, however, usually small or absent altogether.

In the beginning of the process the most noticeable histological change is the relative decrease in the size of the germinal centers and the number of dividing cells in them. With this change the size of the follicles decreases and the number of cells in the diffuse tissue becomes smaller. The amount of fibrous tissue is relatively increased, due to the recession from its fibrous mesh of the lymphocytes of the diffuse tissue. Or there may be an actual hyperplasia of the fibrous tissue, which results in the fibrous hypertrophy already described (p. 45). This recession of lymphocytes is at first most noticeable near the capsule and the trabeculæ which become greatly thickened. It eventually ex-

Fig. 17.

The atrophic tonsil (twenty years). Lymphoid tissue reduced to a mere strip around the crypt. The remainder of the tonsil is a solid mass of fibrous tissue. In the lower right quadrant are several nodules of bone and cartilage.

Fig. 18.

The regressive tonsil of the adult (fifty-three years). The epithelium of the crypt is almost uniformly thick, though the line of demarcation between it and the lymphoid tissue is not sharp. Notice the tendency to keratosis on the surface.

tends to the under surface of the epithelium, more particularly that of the surface, where a well marked fibrous mucosa devoid of lymphocytes may be formed. A similar change, and from the same cause, takes place in the cryptic epithelium; the lymphocytes become less numerous in it, the isolated epithelial fragments are allowed to fall together, and a more or less complete regeneration may take place. It is usually not uniform, however, and often does not occur at all. A tendency to keratosis is noticeable in the cryptic epithelium of many of these tonsils, being a mild form of the so-called pharyngo-mycosis or hyperkeratosis tonsillaris.

As is the case with hypertrophy, atrophy of the tonsils is a relative term. Macroscopically it usually results in a greater or less reduction in the size of the organs. Histologically its essential feature is a decrease in the cellular activity of the lymphoid tissue, which is evidenced by the decrease in the number and size of the follicles, a relative decrease in the size of the germinal centers and in the cell division within them, a decrease in the density and amount of diffuse lymphoid tissue, an increase in the amount of fibrous tissue either relative or actual, and a regeneration of the cryptic epithelium. All degrees of the above changes may be observed, from those in which only careful examination of the follicles shows any change, to those in which the follicles with their germinal centers have entirely disappeared, the diffuse lymphoid tissue reduced to a minimum, and the tonsil practically reduced to a mass of fibrous tissue. Even in this extreme form the crypts remain, with epithelium reverted to the surface or infantile type. I have never found cellular debris in the crypts of the tonsils of advanced atrophy.

Clinically the regressive tonsil is usually small, its size depending upon the extent of the process and the original

size of the organ. In cases of fibrous hypertrophy, however, the tonsils are often very large. The first type seldom gives rise to trouble; in the latter, acute infections, especially peritonsillar inflammations with abscess formation, are very common.

The Anatomy and Histology of the Lingual Tonsil.

The lingual tonsil consists of a variable number of small lymphoid nodules lying on either side of the central line at the base of the tongue. They project backward, so that when enlarged they may touch the tip of the epiglottis. On either side they are in close proximity to the inferior poles of the faucial tonsils. The nodules are usually inconspicuous in children, but become more pronounced in the adult. The common arrangement is two or three prominent and contiguous nodules extending laterally from either side of the central line, making what might be termed a right and a left lingual tonsil; but there may be no actual division line between them. The nodules are sessile and rest on a basement membrane of fibrous tissue analogous to the capsule of the faucial tonsils, but never so compact or highly developed as that tissue. Beneath the capsule is the musculature of the tongue. When sectioned laterally the nodules appear as discrete hemispheres, the mucosa at the bottom of the meagre intervals between them being free from lymphoid tissue. Each presents two or three crypts extending from the epithelial surface nearly to the capsule, which are dovetailed by as many fibrous trabeculæ from the capsule. The crypts are quite simple,—at least I have never seen any evidence of branching—and their length, which is limited by the small size of the nodules, gives them little chance of becoming tortuous. The epithelium is like that of the faucial tonsils—stratified and squamous—and in the crypts presents the same histological

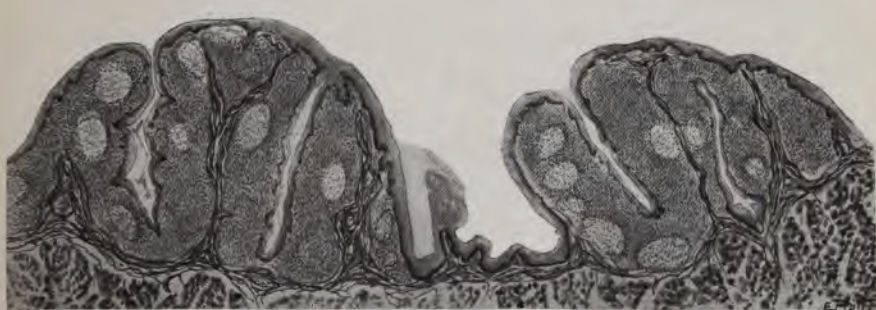

Fig. 19.

Vertical section of the lingual tonsil, from a child of twelve years. These nodules are rather more highly developed than is usual at that age.

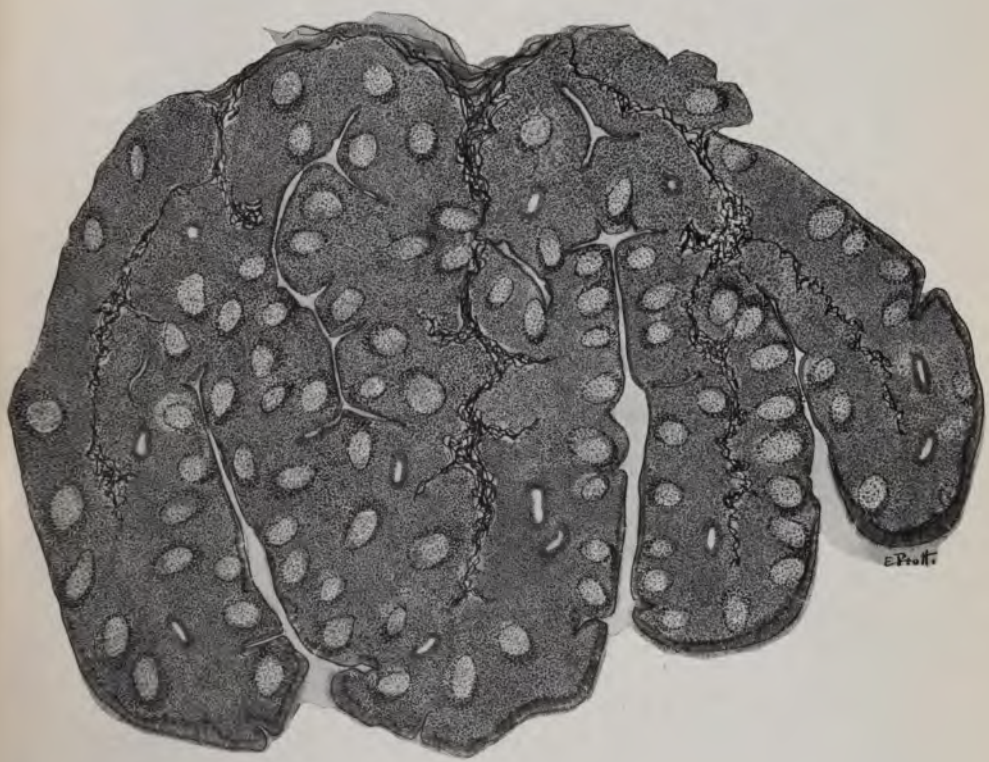

Fig. 20.

Vertical section of the pharyngeal tonsil (eleven years). Epithelium of the columnar-ciliated type, except at the sides near the base where the squamous type has taken its place.

changes produced by the invasion of the lymphoid tissue, but usually less marked. The lymphoid tissue differs in no way from that of the faucial tonsils.

The Anatomy and Histology of the Pharyngeal Tonsil.

The pharyngeal tonsil or adenoid consists of a main mass of lymphoid tissue which hangs from the vault of the nasopharynx just posterior to the nasal choanæ, and of scattered smaller nodules in the mucosa of the fossæ of Rosenmüller and of the posterior pharyngeal wall as low as the level of the palate. Between these latter nodules and those that may often be seen on the posterior wall below the palate there may be no sharp division line. The shape of the main mass differs with its size. It is often sessile and without definite form, melting insensibly into the diffuse nodules of the fossæ and the posterior wall; or it may be pedunculated, with a small and rather attenuated fibrous base, the capsule, from which a variable number of equally delicate fibrous trabeculæ extend into the several fingers of lymphoid tissue of which the mass is composed. These fingers hang from the vault like the leaves of a book, the capsule representing the binding; while between the leaves is a series of antero-posterior clefts extending upward towards the base. The depth of the clefts varies, but it is generally such that when the adenoid is removed *en masse* by the adenotome it is difficult to keep the individual leaves from falling out of the binding. These clefts may be likened to the crypts of the faucial tonsil, though they are developed by a simple folding of the mucosa. From this extended surface a number of irregularly disposed crypts pass into the lymphoid tissue. In the capsule and at times in the fibrous trabeculæ are mucous glands, the ducts of which pass through the lymphoid tissue to the crypts or to the surface.

The epithelium of the pharyngeal tonsil is of the columnar ciliated type. This is true not only of the surface but also of the crypts. On the surface, however, one may occasionally see areas over which the ciliated columnar cells have been replaced by those of the squamous type. These areas are found only on the lateral surfaces. I have never seen them on the more dependent surfaces nor on those of the clefts or the crypts. They may be explained by the well known effect of long continued pressure or irritation on a columnar ciliated epithelium, which is so often seen on the nasal septum. The adenoid is more friable than the tonsil. It is very vascular, though the individual vessels are of small size. This explains the free bleeding that takes place when it is removed, and also the fact that after the first profuse flow of blood the hemorrhage stops and rarely recurs.

The scattered nodules in the rest of the mucosa of the naso-pharynx vary in size. They may fill the fossæ of Rosenmüller completely. The smaller nodules have a single pin-point crypt lined with columnar ciliated epithelium. The larger nodules are simple fusions of two or more smaller nodules. The histologic character of the lymphoid tissue is identical with that of the faucial tonsils.

The Lymphoid Tissue of the Posterior Wall and Lateral Folds of the Pharynx.

The posterior pharyngeal wall consists of an epithelial layer of the stratified squamous variety, a fibrous and a muscular coat. Scattered mucous and serous glands are present in the muscle layer from which excretory ducts pass through the fibrous coat and empty into slight depressions or pits in the epithelium. Normally the lymphoid tissue consists of diffuse collections of lymphocytes in the fibrous mucosa around the excretory ducts of the glands.

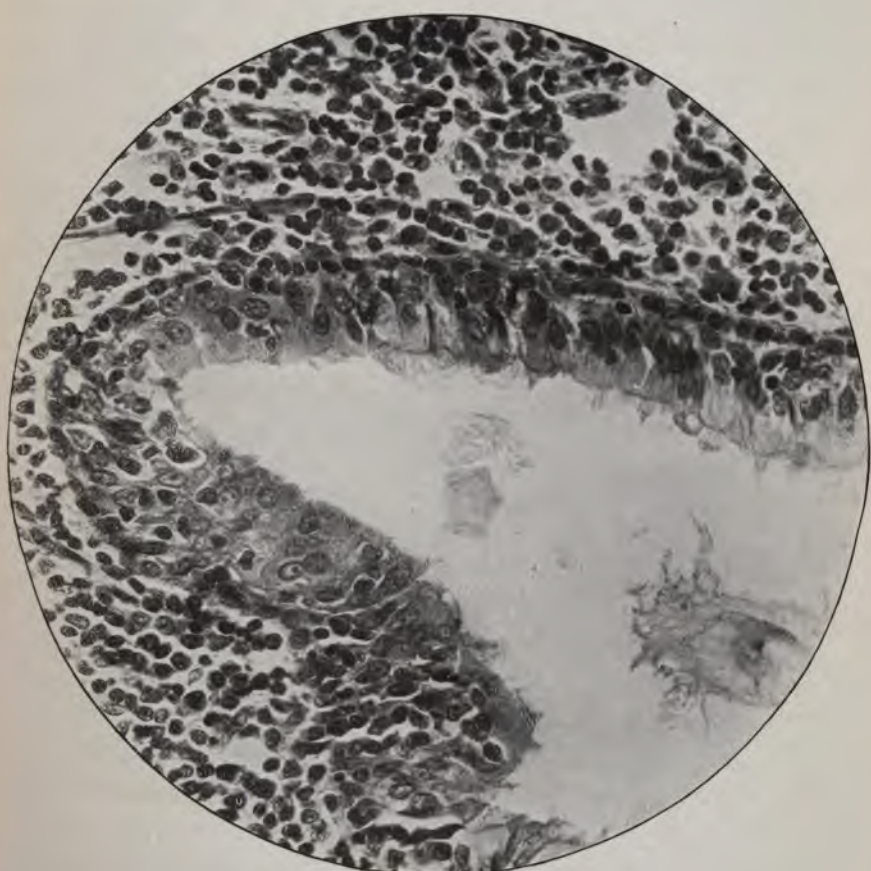

Fig. 21.

Epithelium of a crypt of the pharyngeal tonsil.

Occasional follicles are present. This tissue is inconspicuous and is usually microscopic in character. Under certain conditions it may become augmented both in its diffuse and its follicular elements, so that definite macroscopic lymphoid nodules are formed around the gland ducts in the fibrous mucosa, and the familiar condition known as granular pharyngitis results. The nodules appear on the pharyngeal surface as rounded or oval elevations, pale or deep red in color, and varying in size from the pin-head granule to the large flat nodule a quarter of an inch in diameter. These larger nodules result from the fusion of a number of smaller nodules. In this situation, however, they cannot be superimposed; consequently the nodules are never elevated far above the surface. Each nodule is covered with squamous epithelium, in the center of which is a cup-shaped depression receiving a gland duct. The lymphoid tissue lies in the fibrous mucosa beneath the epithelium, and consists of diffuse tissue in which a number of follicles are embedded, and which surrounds the duct of the gland and forms the prominence of the nodule. Such nodules do not differ histologically from the nodules of the naso-pharynx which constitute part of the pharyngeal tonsil or adenoid. Unlike the latter, however, they can never be considered normal structures in the mucosa.

The mucosa of the lateral folds of the pharynx differs from that of the posterior wall in that the glands are much more numerous and do not lie in the musculature but constitute a definite layer of closely grouped glands lying between the fibrous mucosa and the muscle layer. Numerous excretory ducts pass through the fibrous coat and discharge into minute epithelial depressions similar to those in the posterior wall. The lymphoid tissue here is similar to that of the posterior wall, being slight in amount and

grouped around the gland ducts in the fibrous mucosa. The same conditions that produce the prominent posterior nodules bring about a diffuse infiltration of the fibrous mucosa of the lateral folds, and the resulting lymphoid tissue is similar in every way. Here, however, the individual nodules are fused so as to form a continuous and prominent band of lymphoid tissue running up either side of the pharynx just posterior to the posterior pillar. They may be so prominent as to give the appearance of reduplications of the pillars. They pass upward behind the palate and are lost in the side walls of the naso-pharynx just below the Eustachian orifices.

I have described the nodules of the posterior and lateral walls in conjunction with the other lymphoid tissues of Waldeyer's ring both because they are important parts of that ring and because their structure may be better understood when compared with the other nodules of the naso-pharynx. It must be understood, however, that they are normally of minute size or even microscopic in character, and that when they are enlarged so as to make conspicuous nodules in the pharyngeal wall they are pathological. Even in the latter condition they often cause no symptoms. They sometimes become greatly hypertrophied after the removal of the faucial and pharyngeal tonsils; and such hypertrophy is to be considered vicarious and, to a certain degree, normal.

CHAPTER IV.

THE FUNCTION OF THE TONSILS.

We have no certain knowledge of the function of the tonsils. Naturally enough, this has led, on the one hand, to a great variety of functions being thrust upon them, and on the other, to a denial that they have any function at all. Of the functions attributed to them, many are little better than speculations, advanced without apparent knowledge of their histologic structure—as, that they absorb the products of salivary digestion; that they secrete mucus that aids deglutition; or that they secrete an amylolytic ferment. These theories scarcely need refutation, as they ignore the lymphoid character of the organs and the absence in them of any true granular structure. That the tonsils are atavistic in nature and therefore without function, there is not the slightest reason to believe. They reach their highest development in the higher animals, and in man show great cellular activity throughout the most active period of growth. Their histologic structure, moreover, is identical with that of the other lymphoid nodules throughout the alimentary and respiratory tracts and their physiological significance is undoubtedly the same.

The Hæmopoietic Theory.—Of all the theories of the function of the tonsils, this alone rests on definite histologic findings. It relates to the production of lymphocytes in the germinal centers of the lymphoid follicles. Flemming first pointed out the mitotic division of certain of the cells in the centers of the follicles of lymph glands, the end result of which is the small lymphocyte, and the observation

is universally accepted as true. The origin of the mother cells (lymphoblasts) of the centers, however, and also the further history of the young lymphocytes which they produce by division, are still matters of controversy. Many of these lymphocytes make their way through the epithelium into the crypts, whence they pass into the faucial cavity, or are retained within the crypts and constitute part of the cheesy masses so often found in the tonsil. How many of these cells enter the general circulation through the efferent lymphatics is uncertain. It is scarcely conceivable that of the vast number of lymphocytes produced in an active tonsil of childhood a large proportion enters the crypts; yet if this is not the case, one of two things must happen, —either the majority of them find their way through the efferent lymphatics into the general circulation, or the tonsil becomes enormously hypertrophied through their accumulation in its reticulum. Now hypertrophy of the tonsil does not usually consist in such accumulation, but in the increase in the number of follicles, in their size, in the relative size of the germinal centers and in the increased activity of cell division in these centers. It is also a suggestive fact that the lymphoid nodules of the body show their greatest activity, i. e., activity of cell division in the germinal centers, during the growing years of the child; and that this activity diminishes, or in many of the nodes ceases altogether, at or about puberty. A hæmopoietic function of the nodes serves to explain the coincidence of these phenomena. It is doubtless true that one of the chief functions of the lymph nodules is the production of lymphocytes for the blood; and in this service the tonsils play a very important though by no means indispensable part.

Mention has already been made of Retterer's theory of the genesis of lymphocytes from the cryptic epithelium. (See p. 28.)

The Internal Secretion Theory.—This theory, advanced by Masini,[1] attributes to the tonsils a function similar to that of the suprarenal glands. Masini injected a tonsillar extract into dogs and found a subsequent rise in blood pressure. Both Scheier [2] and Pugnat,[3] however, obtained other results from similar experiments, the first reporting a lowering, and the second no change in the blood pressure. Recently Ciro Caldera [4] has reported the results of an elaborate series of experiments with tonsillar extracts injected into animals. His conclusions are of a negative character, and include the absence of any influence on the circulatory apparatus, of any antibacterial action, and of the production of any typical ferment or internal secretion. Clinical evidence shows conclusively that the tonsils can have no internal secretion, at least none that is peculiar to themselves, for no case has ever been reported in which a tonsillectomy has been followed by symptoms which might be attributed to the loss of such a secretion. If the tonsils have an internal secretion it is one common to all the lymphoid tissues of the body and therefore is of little importance from a practical standpoint.

The Protection Theory.—The theory that the tonsils are organs of protection against bacterial invasion (Gulland, Goerke, Brieger), is one that has been productive of a voluminous literature, but unfortunately little more. The theory owes its conception to the identity of the histologic structure of the tonsils to the lymphatic glands of the body, which delay the spread of infections which take place distally to them. It attributes to the tonsils a protective power to the organism, not only from the bacteria within their own

1 The Internal Secretion of the Tonsil. New York Med. Jour., Sept., 1898.
2 Zur Physiologie der Rachen-und Gaumenmandel. Berliner Laryngol. Gesellsch., 1903.
3 Zur Physiologie der Mandeln. Belg. Oto-laryngol. Gesellsch. Brüssel, 1903.
4 Ricerche sulla fisiologia delle tonsille palatine. Turin, 1913.

crypts, but also from those that enter through the nasal mucosa. That the tonsils have the same power as the lymphatic glands of holding up organisms that are obliged to pass through their tissues to gain access to other parts of the body, seems likely from their similarity of structure; and for this reason we may admit that they undoubtedly exert an influence in preventing absorption of bacteria from the crypts, which must of necessity pass through their substance before entering their efferent lymphatics. Whether this power is due to the phagocytic action of the polynuclear leucocytes, as Gulland [1] believes, or may be explained by the "durchstroemungs" theory of Goerke [2] and his followers who believe that in addition to the stream of cellular elements from the tonsillar parenchyma into the crypts there is a constant flow of fluid through the interstices of the epithelium which prevents the entrance of organisms; or whether the endothelial cells of the reticulum, which are much more active phagocytes than the polynuclear leucocytes, play a rôle here, is a question which we cannot pretend to decide. The experiments of Goodale,[3] Hendelsohns,[4] Wright [5] and others, who have shown that inert powders may be absorbed through the cryptic epithelium into the tonsillar substance; and of Lexer,[6] who applied virulent cultures of staphylococci, pneumococci, and streptococci to the surface of dogs' tonsils, and reported only local and slight infection from the first two organisms but fatal general infection from the last, substantiate what clinical experience so often shows, that whatever the powers of the tonsils may

1 On the Function of the Tonsils. Edinburgh Med. Jour., Nov., 1891.

2 Kritisches zur Physiologie der Tonsillen. Archiv für Laryng., Bd. 19, 1907.

3 Ueber die Absorption von Fremdkörpern durch die Gaumentonsillen, usw. Archiv f. Laryng. Bd. 7.

4 Verhalten des Mandelgewebes gegen aufgeblasene pulverförmige Substanzen. Archiv f. Laryng. Bd. 8.

5 The Difference in the Behavior of Dust from that of Bacteria in the Tonsillar Crypts. New York Med. Jour., Jan. 6, 1906.

6 Die Schleimhaut des Rachens als Eingangspforte pyogener Infectionen. Archiv f. klin. Chirugie, Bd. 54.

be in this particular, they are very often inadequate to prevent infection taking place or in limiting such infection to their own tissues. The question must ever be one of the mastery between two contending forces; on the one hand the number and virulence of the organisms in the crypts, and on the other the forces of resistance of the individual, whether they be local and inherent in the tonsil, or general and depending on antibacterial chemical conditions of the blood and lymph.

Of the theory of protection by the tonsils from organisms absorbed through the nasal mucosa, there is little to be said in defense. The theory would be tenable only if the lymph stream from the nasal mucosa, or at least a large part of it, could be shown to pass through the tonsil before its distribution to more distant parts. We would then have to admit that the tonsils play the same protective rôle for the nasal mucosa that the axillary lymph glands, for example, play for the arm, and that infections entering through that mucosa would, if not too intense, be taken care of by the tonsils. But no such intimate lymphatic connection between nasal mucosa and the tonsils has ever been demonstrated. As Fraenkel first pointed out, acute infections in the nose are often followed by an acute tonsillitis. But the reverse order of the infection is not unusual and the sequence in both instances is probably due to infection through the blood rather than through the lymphatics. Lénárt[1] has demonstrated that if suspensions of colored powders are injected into the nasal mucosa of dogs, the tonsil, not only on the injected side, but even on the opposite side, will be found to contain some of the colored particles. He deduced from this a lymphatic connection between the nasal mucosa and the tonsil. The amount of coloring matter that entered the

1 Lénárt, Z.: Experimentelle Studie über den Zusammenhang des Lymphgefässsystem der nasenhöhle und der Tonsillen. Archiv f. Laryngologie, bd. 21, 1909.

tonsil was, however, according to his sections, inconsiderable, while the amount that entered the superior cervical lymph nodes was very large. Even admitting that his contention is true, and that his experiments prove a lymphatic connection between the two,—they also show that this connection must be very slight and that, as was well known before, the efferent lymphatic stems from the nasal mucosa posteriorly pass to the retropharyngeal or superior cervical nodes. If organisms entering through this mucosa passed to the tonsils and the cervical nodes in the same ratio as the colored particles of Lénárt's experiments, then the individual would have to depend very largely, as indeed he probably does, upon the cervical nodes for protection.

The Eliminating Theory.—Ashhurst [1] asserts that the tonsils act as eliminating organs during the common acute infections; that the inflammation of the tonsils in such infections is secondary, and that this may be ascribed to an effort on the part of the lymphoid nodules to eliminate the offending organisms. A case of acute tonsillitis following a septic lesion of the hand and arm is so interpreted by him. That such secondary involvement of the tonsils does take place during the course of septic infection in other parts is true. I have seen two cases of acute streptococcus tonsillitis that were secondary to septic conditions of the hand accompanied by septicæmia. But it seems to me that Ashhurst's interpretation of the phenomenon is somewhat fanciful, and that it may be explained in a much simpler way, namely, that the tonsils and the other lymphoid nodules of the pharynx are extremely susceptible to infections that have entered the blood stream.

The Immunity Theory.—This theory,[2] the product of scientific imagination, pictures the tonsils as the vaccine

1 Amer. Jour. Med. Sciences, July, 1909.

2 Good, R. H.: Laryngoscope, vol. xix, 1909, page 489.
Digby, K. H.: The Function of the Tonsils and the Appendix. Lancet, Jan. 20, 1912.

laboratories of nature. It regards the crypts as so many culture tubes in which organisms are cultivated, and toxins generated and absorbed in just sufficient doses to produce the necessary antibodies to immunize the individual against the active invasion of the organisms themselves. The tonsils of the child are therefore of great importance, until such immunity to the prevalent bacteria of his environment has been acquired. The theory is a very pretty one and cannot be confuted. A study of the comparative incidence of the acute infections of childhood in those who have had their tonsils removed and those who have not might throw some light on this subject. A very large number of cases would be necessary to avoid the element of chance.

From the clinical standpoint the function of the tonsil has its most important application to the question of operative procedures; whether a partial or complete removal is to be recommended when symptoms demand operative interference. The advocates of tonsillotomy have ever had visions of the possible loss of some unknown function, indispensable to the individual, which would inevitably follow the complete removal of the tonsils. Spite of the fact that, of the countless number of tonsillectomies done during the past few years, not one has been shown to have had any untoward result that could be attributed to the loss of any possible functionating power; spite of the fact that the histologic structure of the tonsils shows plainly that their function, whatever it may be, is identical with that of the other lymphoid nodules of the body, and therefore one that would no more be missed in its removal than the function of a small area of skin would be missed; spite of all this, the old inadequate tonsillotomy, or worse still, galvano-cautery applications to the crypts, are still done by many men because of a phantom function of the tonsil. On the other hand, the idea that the tonsils have no function or that it is one

that may be easily spared, has led, in many quarters, to the condemning of all tonsils that show their heads, so to speak, beyond the faucial pillars, even when no symptoms are present, or only such as could be attributed to them by the utmost stretch of the imagination. It is difficult to say which attitude is productive of the more mischief. On the one hand many patients are allowed to suffer the ill effects of chronic toxic absorption or of recurring acute inflammatory conditions, when a simple enucleation is all that is necessary to give them complete relief; while on the other, perhaps a much larger number of patients are put through a needless operation which a more careful study of the individual case might obviate. The tonsils should, by all means, be respected as functionating organs, especially in children, and should never be removed without adequate cause. But when such cause exists, the loss of their functionating power should not be used as an argument against their complete extirpation.

CHAPTER V.

THE GENERAL PATHOLOGY AND BACTERIOLOGY OF THE TONSILS.—THEIR RELATION TO SYSTEMIC INFECTIONS.

Practically all of the pathological conditions in the tonsils, with the exception of the neoplasms and certain of the specific infections, are brought about by the peculiar anatomical structure of the crypts and their tendency to retention of cellular debris. The crypts are tortuous and deep, extending practically to the capsule; their walls are held in close apposition by pressure of the surrounding lymphoid tissue, and the mouths of those that empty either anteriorly or superiorly may be partially closed,—the first by the plica triangularis and the second by the hood-like superior wall of the supratonsillar fossa. The supratonsillar crypts have the added disadvantage of draining upward. The result is that a certain amount of debris is found in the crypts of all tonsils. Bacteria from the faucial cavity enter the crypts and find there a very congenial soil for development. The cryptic epithelium is thin, showing usually only one or two layers of cells, and in many places is so masked by the lymphoid tissue as to be difficult of demonstration. It offers little mechanical resistance to the entrance into the parenchyma of the tonsil of foreign particles from the crypts, as has been shown by the experiments of Goodale, Hendelsohns and others. The conditions seem to be ideal for the invasion of bacteria or the absorption of the toxic products of their growth.

The above conditions do not obtain in the tonsil at birth

but are the result of a gradual development and are usually not marked until well into the second year of life. At birth the tonsils are small and the crypts comparatively shallow. The lymphoid tissue is not active, lymphoid follicles with their germinal centers usually being absent until about the fourth month of infancy. The cellular elements entering the crypts from the lymphoid tissue are therefore inconspicuous. Many of the crypts are still in the formative stage with central epithelial cores. No bacteria are present. The cryptic epithelium is for the most part essentially like that of the surface, compact and many cells in thickness, degeneration due to the invasion of lymphoid cells being absent or only slight. Plasma cells are absent from the parenchyma.

It is after the appearance of the follicles with their germinal centers that the tonsillar conditions of childhood gradually develop. The tonsils grow rapidly and in consequence the crypts become deeper and more tortuous. The number of lymphocytes passing through the epithelium into the crypts is greatly increased, thereby increasing the amount of debris within the crypts; while its retention is rendered more probable by the pressure on the cryptic walls of the rapidly growing lymphoid mass. Degeneration of the cryptic epithelium usually begins after the sixth month of infancy and is well advanced by the end of the first year. The age at which these changes take place, however, is subject to considerable variation.

Bacteria appear in the tonsillar crypts at about the time of the bacterial invasion of the intestinal canal (24 to 72 hours after birth), and plasma cells appear in the lymphoid tissue shortly after,—according to Davis [1] during the second or third week of life. They are to be found especially under the epithelium of the crypts, around the blood vessels and in the vicinity of the fibrous trabeculæ. They are most nu-

1 Davis, D. J.: On Plasma Cells in Tonsils, Jour. of Infec. Diseases, Vol. 10, 1912.

merous in those tonsils in which retention in the crypts is marked. As they are usually present in chronic inflammatory lesions, they are probably in the tonsils an expression of chronic irritation due to absorption of bacterial toxins from the crypts.

It will be appreciated that the so-called buried tonsil with the very extensive and almost closed supratonsillar fossa extending high into the palate is much more liable to marked cryptic retention than is the prominent pedunculated tonsil which has a shallow and usually open supratonsillar fossa. The latter type of tonsil averages the smaller of the two, the mouths of its crypts are more open and the crypts themselves less tortuous and deep.

Acute inflammatory attacks and hypertrophy are important factors in increasing the difficulty of drainage from the crypts; the first by creating inflammatory adhesions between their epithelial walls and subsequent cicatricial contraction; the second by increasing the depth of the crypts and the amount of cellular material that passes into them from the lymphoid tissue.

The debris of the crypts is largely cellular—lymphocytes, polynuclear leucocytes and exfoliated epithelium—containing also cholesterine crystals, hyaline material, and large numbers of bacteria. It is of a cheesy consistency, of a yellowish-white or at times greenish color, and often has a very offensive odor. It may appear at the openings of the crypts, when the condition is evident to the most casual inspection; or a careful examination of the anterior and supratonsillar fossæ with a probe may be necessary to discover its existence. Often, however, the most painstaking examination fails to demonstrate it, the tonsil having all the appearances of a perfectly normal organ; yet when the root of the tonsil is compressed by the wire of the snare during tonsillectomy, large amounts of foul decomposing debris are

squeezed from the depths of the crypts and appear on the surface. In many of these cases it is impossible for any one to tell the condition of the deeper parts of the crypts until the tonsil is removed, as it is at their blind ends, in close proximity to the capsule, that retention and bacterial growth are the most marked. It is here also that the small chronic abscesses of the tonsil are most often found, being distinctly visible through the translucent capsule of the excised organ.

Latent primary tubercular foci are sometimes found in the tonsil, the percentage of cases varying with different observers. In my own series I have found such foci in three out of one hundred and fifty tonsils, removed from patients with no evidence of tuberculosis elsewhere. The lesions consist of discrete or confluent tubercles, without round celled infiltration or the slightest suspicion of caseation. I mention this form of tuberculosis here because, like deep cryptic retention and deep chronic abscess formation, it usually gives no clinical indication whatever of its existence and is not discovered until the tonsil is removed.

The Bacteriology of the Crypts.—Many varieties of organisms have been isolated from the tonsillar crypts. Of these the streptococcus is the most frequently present, being found in so large a percentage of all tonsils examined that it may almost be said to be normally present in the crypts. Of 113 tonsils examined by Davis,[1] removed from patients with joint lesions, endocarditis, or nephritis suspected to be due to absorption from the crypts, or who gave histories of repeated attacks of acute tonsillitis, 90 showed hemolytic streptococci as the predominating organism and in nearly pure cultures. Dwyer and Gignoux[2] have reported a slightly smaller percentage from cultures taken from the

1 Davis, D. J.: Bacteriology and Pathology of the Tonsils. Jour. of Infec. Diseases, Vol. 10, 1912.

2 Dwyer, J. G. and Miss Gignoux.: Bacteriological Examination of the Tonsillar Crypts, Manhattan Eye, Ear and Throat Hospital Reports, Feb., 1912. No. XIII.

crypts of essentially normal tonsils. In the remainder of Davis' series the predominating organisms were as follows: pneumococcus, 8 cases; staphylococcus albus, 6 cases; influenza bacillus, 3 cases; diphtheria bacillus, 2 cases; and the bacillus mucosus capsulatus, 1 case. The series of Dwyer and Gignoux gives a much greater variety of organisms, among others the bacillus pyocyaneus and Friedländer's bacillus, while the Klebs-Loeffler bacillus was found in 7 per cent. and the staphylococcus in 28 per cent. of all cases, much higher percentages in both instances than Davis' series showed. Dwyer's cultures were all taken from tonsils *in situ,* however, and surface contamination could scarcely be avoided, while Davis made his cultures from the deep crypts of excised tonsils with every precaution against surface contamination. His results probably represent accurately the usual bacterial flora of the crypts.

Streptococci isolated from the crypts show considerable variation in cultural characteristics and in the lesions they produce when injected into animals. In the deep chronic abscesses and in the sealed crypts of the tonsils the predominating organism is usually the *Streptococcus hemolyticus* (pyogenes), while the *Streptococcus viridans,* an organism closely related to the pneumococcus and referred to by that name in the articles of Davis, is usually a surface growth.[1] In animal experimentation the *S. hemolyticus* regularly produces joint lesions while the endocardium is but rarely affected. The exact opposite is true of the *S. viridans.* Other members of the streptococcus group (the *S. epidemicus* [Davis]), which is the usual organism of the milk-borne epidemics of septic sore throat, the *S. mucosus* and the *S. pneumoniæ* (pneumococcus), occupy places in the order named intermediate to the first named organisms, both in

1 Billings, F.: Chronic Focal Infection as a Causative Factor in Chronic Arthritis. Jour. Amer. Med. Assn., Sept. 13, 1913.

their cultural and morphological characteristics and their affinity for the joints on the one hand or the endocardium on the other. The *S. mucosus* and the *S. pneumoniæ* occasionally are found in the crypts of tonsils which have given rise to no symptoms. The *S. epidemicus*, however, occurs only in those cases the clinical characters of which have given the organism its name and is always of extraneous origin, usually being introduced in the milk supply. The work of Rosenow [1] and of Davis [2] indicates that all of these may be forms of one and the same organism,—at least transmutation from one form to another has been shown to take place with changes in cultural conditions, and the character and localization of the experimental lesions in animals may be determined with some degree of accuracy by the phase of transmutation of the organism.

There seem to be no cultural, morphological or pathogenic differences between the organisms isolated from the crypts of normal tonsils (i. e., those that have given rise to no symptoms, either local or secondary), and those recovered from the tonsils of patients with any of the various infectious lesions supposedly of tonsillar origin. In the series of Davis, only the cases of endocarditis differed from the average in the character of the predominating organism of the crypts. The *S. viridans*, usually a surface growth and present in the crypts only in about 4 per cent. of all cases other than those of endocarditis, was found in the tonsillar crypts in pure cultures or in predominating numbers in 40 per cent. of the patients with this lesion. The organism is apparently identical with the so-called endocarditic coccus of Rosenow commonly isolated from the lesions of the endocardium. So great a proportionate increase in its oc-

1 Experimental Infectious Endocarditis. Jour. of Infec. Diseases, Sept., 1912.

2 Bacteriologic and Experimental Observations on Focal Infections. Arch. Int. Med., April, 1912. Interrelations in the Streptococcus Group, etc. Jour. of Infec. Diseases, May, 1913.

currence in the tonsillar crypts of patients with endocarditis suggests the possibility of cultures from the crypts being of service in establishing the source of many cardiac infections. Effectual means of destroying the organisms on the surface of the tonsil would have to be taken, as the *S. viridans* is nearly always found there. This could easily be done by burning a small surface immediately surrounding the mouth of a crypt with the electro-cautery and then introducing a platinum wire deeply into the crypt.

The tubercle bacillus undoubtedly is present in the tonsillar crypts of a small percentage of individuals without demonstrable tubercular lesions, either in the tonsil or elsewhere. Dieulafoy,[1] by the introduction of tonsillar fragments into animals, produced tubercular lesions in 8 of 61 cases (12 per cent.); while the combined statistics of a large number of investigators show that primary tuberculosis of the tonsil is found only in about 6 per cent. of all cases.[2] Dieulafoy's large percentage of positive results by inoculation was probably due, not to the larger percentage of tonsils with tubercular lesions, but to the presence in the crypts of free tubercle bacilli which had not penetrated to the tonsillar parenchyma.

Organisms resembling the fungus of actinomycosis are frequently present in the detritus of the crypts.[3] They are apparently saprophytic in character, invading the tissues only under very exceptional conditions of injury or diminished resistance on the part of the host. Their identity with true actinomyces is denied by Davis.[4]

1 Die larvirte Tuberculose der 8 Mandeln, Acad. de Med., April 30, May 7 and 14, 1895.

2 Wood, G. B.: The Tonsils and Tuberculosis, Penn. Med. Jour., June, 1912.

3 Lord, F. T.: Jour. Amer. Med. Assn., Vol. 55, Oct. 8, 1910.
Grosvenor, L. C.: Laryngoscope, March, 1911.

4 Jour. of Infect. Diseases, Jan., 1914.

The Relation of the Tonsils to Systemic Infections.

That many systemic infections arise through the entrance into the blood or lymph streams of organisms from the tonsillar crypts, either with or without primary lesions in the tonsils themselves, is now almost universally admitted. The infections may be divided roughly into two groups; first, those due to chronic conditions in the tonsils themselves and to the absorption of organisms indigenous to the crypts; and second, those that are secondary to tonsillar lesions caused by organisms from an extraneous source, as, for example, the streptococcus infections resulting from a contaminated milk supply. Though the latter class of infections are often of a high degree of virulence and may result in fatal general sepsis or grave localized lesions, they are to be regarded rather as accidents than as due to any inherent conditions in the tonsils themselves, beyond perhaps a general susceptibility to infection. They may be said to be of tonsillar origin only in that the infection is primary in the lymphoid nodules of the throat. The second class of infections are due to the chronic pathological conditions in the crypts or in the tonsillar parenchyma described in the foregoing paragraphs. They alone can be directly attributed to the tonsils and for that reason they are the only ones that will be considered here. It must be remembered that the other lymphoid nodules of the pharynx may be responsible for many of these infections, but that on account of the shallowness of their crypts or because of other reasons for freedom of drainage, their importance in this respect is slight compared with the faucial tonsils. This is especially true of the lingual nodules.

Among the infections that have been attributed to this source are acute or chronic arthritis, endocarditis, pericar-

ditis, chorea, acute or chronic nephritis, neuritis, osteomyelitis, appendicitis, peritonitis, pulmonary gangrene, infectious jaundice, cervical adenitis of simple inflammatory or tubercular origin, and chronic toxemia without localized lesions other than those in the tonsils themselves. This is by no means a complete list of the infectious processes that have been reported as occurring secondary to tonsillar infection. In many of them the relation of the tonsils to the disease has not been above question; but as we must admit that septicæmia of a low or high grade of virulence may be of tonsillar origin, it is evident that the infection may manifest itself by the most varied localizations, depending on the character and virulence of the organism and the conditions of resistance present at the time in the different tissues. Nevertheless the joint and heart lesions, with the closely associated Sydenham's chorea, subacute and chronic parenchymatous nephritis, the glandular lesions of the neck and the chronic toxemias without localized lesions are by far the most important of these infections, both on account of the frequency of their occurrence and because the clinical and pathological evidence, while perhaps not conclusive, is often of such a nature as to leave little doubt of their tonsillar origin.

The close relationship that often exists between acute articular rheumatism and acute tonsillitis has been observed for many years. At times the joint and throat symptoms are simultaneous in their onset, while again the tonsillitis precedes the arthritis and may even completely subside before the joint lesions develop. Subacute or chronic infectious arthritis is often associated with recurring attacks of tonsillitis, the tonsils lighting up previous to each fresh exacerbation of the joint lesions; or the tonsils may be the seat of a low grade chronic inflammation lasting for months with frequent outbreaks of a more acute character. Endo-

carditis and pericarditis not infrequently follow even very mild attacks of acute tonsillitis. Chorea may be present, with or without cardiac or arthritic symptoms. Acute, subacute or chronic parenchymatous nephritis are beginning to be recognized as possible sequelæ of tonsillar infections. This intimate association of joint, heart and kidney lesions with tonsillar inflammations and the sequence of the symptoms strongly suggests that the tonsils may be the primary seat of infection. Their involvement might, of course, be secondary to a primary infection elsewhere; indeed, such secondary acute inflammations of the tonsils at times occur in the course of septicæmias of other focal origin. The history and sequence of events in these cases, however, are usually obvious, as they are also in the inflammatory conditions of the tonsil which follow acute nasal lesions.

The bacteriological evidence that the tonsils may be the primary focal point of these systemic infections is not absolutely conclusive; nevertheless it makes a strong connecting link between the clinical evidence and that presented by the effects of enucleation on the cardiac, arthritic or renal lesions. Poynton and Payne[1] isolated from the crypts of a patient with acute tonsillitis a diplococcus (diplococcus rheumaticus) which was identical with one they had previously found in the lesions of arthritis, endocarditis and pericarditis. Both organisms produced similar joint and heart lesions in animals. Since this observation was made much conflicting evidence has been presented concerning the etiology of acute rheumatic fever, the character of the cocci isolated from the joints by different investigators showing considerable diversity. The recent work of Rosenow[2] goes far towards reconciling these differences. He has isolated from the joint nodes and exudate of acute rheu-

1 The Etiology of Rheumatic Fever. Lancet, 1900, Vol. II, page 861.
2 Reported by Billings, F.: Jour. Amer. Med. Assn., Sept. 13, 1913.

matism three types of cocci which in their morphology, cultural characteristics and virulence stand midway between the S. hemolyticus and the S. viridans. By varying the cultural conditions the character of the cocci was made to change from one form to another. They produced multiple non-suppurative arthritis, endocarditis and pericarditis in the same animal; but by changing the strain through changed cultural conditions, their affinities could be transferred to the muscles, myocardium and kidney. Apparently these organisms are not found in the tonsillar crypts; but as Rosenow [1] and Davis [2] have shown that transmutation of form and pathogenic properties may take place under certain conditions between the various members of the streptococcus group, it is probable that either the S. hemolyticus or the S. viridans of the crypts may undergo transmutation to one of these intermediate forms after entering the blood current.

In cases of subacute and chronic arthritis the deep crypts of the tonsils almost invariably show pure cultures of the S. hemolyticus, which produce acute or chronic multiple arthritis when injected into animals. The same organism may usually be recovered from the experimental lesions. Their presence in the tonsillar crypts of patients with joint lesions, and the experimental results in animals are suggestive of a causal relationship of the tonsils to the disease, but cannot be accepted in any other light, as a large percentage of tonsils causing no symptoms contain the same organism; and it is well known that streptococci from any source may produce experimental arthritis in animals.

The relation of the S. viridans of the tonsils to lesions of the endocardium is again suggestive only. This organism is commonly found in the mouth and pharynx but is seldom

1 Experimental Infectious Endocarditis. Jour. of Infec. Diseases, Sept., 1912.
2 Interrelations in the Streptococcus Group. Jour. of Infec. Diseases, May, 1913.

present in the tonsillar crypts. It was, however, obtained by Davis in practically pure cultures in the crypts of 40 per cent. of tonsils removed from patients with endocarditis which was supposedly of tonsillar origin. It may usually be isolated from lesions of the endocardium and when injected into animals almost invariably localizes on the heart valves. It rarely causes joint lesions.

The most convincing evidence we have that the tonsils are among the most important of the primary foci from which systemic infection may take place is derived from the post-operative results of tonsillectomy. Joint, heart and kidney lesions often show such marked improvement as to leave no doubt whatever of the origin of the infection. This applies not only to those cases in which local tonsillar symptoms are or have been present, but also to many cases in which such symptoms are absent, the tonsils being small and without demonstrable suppurative lesions or retention in the crypts. In that form of chronic toxemia or septicæmia evidenced by general malaise, anæmia, loss of weight, etc., but without distinctly localized lesions, the improvement following enucleation of the tonsils is often immediate and rapid.

In the individual case the clinician is seldom in a position to say with certainty that a given systemic infection is of tonsillar origin. In those cases in which cryptic retention or suppuration is manifest or in which tonsillar inflammation is one of the features, he may proceed on the assumption that the tonsils are the source of the infection. Often, however, when the tonsils are undoubtedly responsible, they show nothing on clinical examination that would suggest it. The very worst conditions of retention in the deeper parts of the crypts or of chronic abscess formation in the vicinity of the capsule, may exist in a small and perfectly normal appearing tonsil. Under these conditions it is only by a process of exclusion that the tonsils may be indited as the

possible offenders; for it must be remembered that they are only one of many different sources from which systemic infections may arise. The condition of the teeth and gums, the gastro-intestinal and genito-urinary tracts, the ears and the nasal accessory sinuses are perhaps the most important to determine. After other sources of the infection have been eliminated as far as possible, the removal of the tonsils may be advised as a therapeutic measure even when clinical examination fails to show any pathological condition in them. The results of tonsillectomy justify this. Often the infectious processes show marked amelioration or even total subsidence after the operation.

In view of the fact that Sydenham's chorea is so often associated with rheumatism and endocarditis and also because of the improvement that occurs in many patients with chorea after the removal of the tonsils and the adenoid tissue of the vault, it seems likely that the infectious agent may be introduced from this source.

That the tonsillar crypts may be the atrium of infection in tuberculosis is an established pathological fact. Tubercular lesions have been repeatedly produced by the introduction of pieces of excised tonsils into animals. The combined results of many investigators show that about 6 per cent. of all tonsils have latent primary tubercular lesions. I have found only three cases of latent tonsillar tuberculosis out of 150 tonsils removed from patients without demonstrable tuberculosis elsewhere. In two cases of tubercular glands of the neck which were excised the tonsils showed tubercular foci of the same character. Clinically there are no signs by which the existence of such foci may be determined. They are usually found only accidentally after the removal of the tonsils. Tubercular cervical adenitis frequently occurs, either secondary to the lesions in the tonsils, or in some cases through the passage of bacilli from the crypts into

the lymphatics without the production of primary foci in the tonsil.

The possibility of tubercular lesions of the pulmonary apices arising through this channel has been raised by Grober,[1] who has demonstrated a direct lymphatic connection between the tonsils and the parietal pleura of the apical vault, through the deep cervical and supraclavicular glands. From the results of his experiments he argues that disease of the pulmonary apices may arise from bacilli entering through the tonsils, the final step in the process being accomplished through inflammatory adhesions between the parietal and pulmonary pleuræ. While it may be admitted that pulmonary infection may take place in this way, it is probably of very rare occurrence.

The Relation of Age to Tonsillar Infection.[2]—From the foregoing account it will be seen that the cryptic conditions in the majority of tonsils are such that local or systemic infection may result whenever the powers of resistance of the individual are for any reason lowered. This is especially true of the tonsil of the child and in that of fibrous hypertrophy of the adult. In the former the cryptic epithelium is so thin that it offers little mechanical resistance to the entrance of organisms, while the debris in the crypts is usually considerable in amount. The great cellular activity of the lymphoid tissue at this age probably has much to do with the prevention of infections; but whether the protecting agency is the outward flow of lymphocytes into the crypts or the phagocytic power of the polynuclear leucocytes or the endothelial cells of the reticulum is problematic. In the tonsils of fibrous hypertrophy of the adult the crypts are particularly tortuous and show irregular constrictions and dilations brought about by fibrous contraction. The

1 Die Tonsillen als Eintrittspforten für Krankheitserreger, besonders für den Tuberkelbazillus. Klin. Jahrbuch, 1905, XIV.

2 Barnes, H. A.: Annals of Otology, Rhinology and Laryngology, Dec., 1911.

epithelium of the crypts is for the most part still in the attenuated state, though an irregular thickening may be present, while whatever protection active lymphoid tissue may exert is wanting. Neither the tonsil of infancy nor the small regressive tonsil of the adult are as liable to infection, as in both varieties the cryptic epithelium is thick and cellular retention slight. (See Figs. 10, 11, 12, 13, 14 and 18.)

While these local conditions are of great importance in determining individual susceptibility to infection, it is probable that relative immunity plays the most important rôle here. Tonsils of patients presenting no other symptoms than those due to hypertrophy often show the worst cryptic conditions, while those that are associated with glandular or systemic infection may be small and retention in the crypts not specially pronounced. Difference in virulence of the organisms in the crypts cannot wholly explain this, as under usual conditions their pathogenicity in animals seems to be fairly uniform; nor can the difference in phagocytic activity of the cells of the tonsillar parenchyma be held wholly accountable. These forces undoubtedly have an influence; but the antibacterial action of the blood and lymph, which differs so widely in relation to all bacterial diseases, would seem to be the chief determining factor.

CHAPTER VI.

DISEASES OF THE TONSILS.

Acute Tonsillitis.—Acute tonsillitis is an infectious disease usually due to one of the organisms of the streptococcus group, though the pneumococcus, the Staphylococcus aureus or albus, or the colon bacillus may be the infectious agent. It occurs in two forms,—the sporadic and the epidemic. A sharp distinction between the two cannot always be made, but in typical cases the difference is sufficiently marked to warrant considering them as different entities. The first will be described under the name Acute Follicular Tonsillitis,—a somewhat inaccurate term, since the entire parenchyma of the tonsil is involved in the inflammatory process, but retained here because the changes in the follicles are more marked than elsewhere. The second may well be named Acute Septic Sore Throat,—a term that has long been applied in England to epidemic tonsillitis arising from infected milk. Until recently the disease was almost unknown in this country, but has become familiar during the past three years through the disastrous epidemics in Boston, Baltimore and Chicago.

Acute Follicular Tonsillitis.—Etiology.—In a large percentage of the cases the infecting organism is the Streptococcus pyogenes. The Streptococcus viridans, the pneumococcus, the Staphylococcus albus and aureus are occasionally responsible. Very rarely the colon bacillus is found. The infectious organism is, in many cases at least, one of those chronically present in the crypts of the tonsil. The anatomical conditions that favor bacterial growth in the

crypts have been described (p. 63). What the general conditions may be that allow organisms, ordinarily kept at bay, to make a breach in the line of defence and enter the parenchyma of the tonsil, are but imperfectly understood. Possibly there may be changes in the cultural conditions in the crypts, which periodically increase the virulence of the organisms there; or, what is more likely, the defence itself is temporarily weakened. The deleterious action of bacterial toxins of the crypts on the epithelium has been assigned as a cause. It seems hardly probable, however, that this extremely attenuated tissue, at least as it is found in the tonsils of children, can be of any great importance in this regard; it is much more likely that vaso-motor changes in the lymphoid tissue itself, or temporary reduction in the antibacterial powers of the blood and lymph, are responsible for the invasion. Exposure to cold and wet is one of the most common means of bringing about this lowered resistance. The relation of the disease to rheumatism has been discussed (p. 71). It occurs at all seasons of the year but is much more common during the late winter and spring months than at any other time. It may be contagious, but probably only by very intimate contact.

Pathology.—The tonsil is increased in size, due to diffuse proliferation of the cells of the parenchyma and to active hyperæmia of the organ. The crypts are filled with purulent exudate, consisting of exfoliated epithelium, polynuclear leucocytes, lymphocytes and bacteria. In the more severe cases the exudate is fibrinous. The most noticeable histological changes are to be seen in the follicles. Here increased proliferation, both of the lymphoblasts and of the endothelial cells of the reticulum, results in enlargement of the germinal centers and in a marked accentuation of the seal ring effect of the peripheral lymphocyte zone, which is greatly broadened on the side nearest the adjacent crypt.

Cellular fragments are numerous within the centers, and appear to be taken up rapidly by the endothelial phagocytes, the cytoplasm of which may show numbers of such fragments. The changes in the diffuse tissue of the parenchyma are not so marked, and consist in an increase of all its cellular elements. The polynuclear leucocytes are relatively increased. Plasma cells are not greatly increased above the numbers usually found in tonsils of childhood and are most conspicuous just beneath the epithelium of the crypts. The blood vessels show an active hyperæmia, being crowded with red and white corpuscles, while the cells of their endothelial lining are swollen and stand out prominently. Endothelial phagocytes are only occasionally seen. The process may stop short of abscess formation, which never, apparently, occurs in the interfollicular tissue but frequently takes place in the follicles themselves, being dependent on the intensity of the inflammatory process. It may involve many or only a few follicles. All stages may be seen in the same tonsil, from the circumscribed collection of polynuclear leucocytes and micrococci in the center of the follicle, to the fully developed abscess which has discharged into the nearest crypt. Bacteria are seldom seen in the interfollicular tissue of the parenchyma.[1]

Symptoms.—The onset is abrupt, a definite chill or chilly sensations, malaise, pain in the back and limbs, and a sore throat coming on in quick succession or simultaneously. The temperature goes up rapidly, reaching 103° to 105° within the first twenty-four hours. Prostration may be marked and is entirely disproportionate to the extent and severity of the local process. The tonsils are swollen and red and their surfaces studded with discrete white spots—the protruding exudate of the crypts. The other lymphoid

1 The best description of the pathology of acute tonsillitis is that of Goodale, which appeared in The Jour. of the Boston Soc. of the Med. Sciences, Jan., 1899.

nodules of the pharyngeal ring are involved in many cases. Enlargement of the tonsillar cervical glands is the rule, and gives rise to tenderness and lameness in that region. Swallowing is painful and may be difficult when the tonsils are excessively swollen. The voice is thick and at times has a nasal quality. The tongue is furred and the breath heavy and offensive. The inflammation may extend to the Eustachian tube and the middle ear, but pain in the ear is not necessarily an indication of middle ear involvement, as the symptom is frequently a reflex one. The urine is scanty and high colored. Febrile albuminuria is not uncommon. More rarely acute nephritis develops. The duration of the disease is short, the acute symptoms usually subsiding within three or four days, leaving the patient with nothing worse than a general weakness, which may, however, be profound and somewhat protracted.

The severity of the symptoms of acute tonsillitis varies within wide limits. The foregoing description may be taken as typical of a case of moderate severity and without complications. There are, however, many cases in which the patient is at no time ill enough to be confined to his bed or even to be kept within doors. Such cases are particularly apt to be recurrent, usually giving a history of being "subject" to sore throat at varying intervals. The history of previous attacks is perhaps not so common in the more severe cases.

Complications.—The infection may extend to the Eustachian tube and the middle ear. Peritonsillar abscess occasionally develops, though it is not so common as in the epidemic form of tonsillitis. Acute rheumatism, chorea, infectious arthritis, endocarditis and pericarditis, and acute nephritis cannot be said to be rare sequelæ. Erythema multiforme and nodosum have been reported.

Diagnosis.—There may be great difficulty in distinguish-

ing acute tonsillitis from diphtheria. Usually the discrete white spots of exudate, friable and easily removed without leaving a bleeding surface, are sufficiently characteristic. When, however, two or more spots coalesce so as to form a broad patch, doubts as to the nature of the process may arise. This is particularly the case when suppuration in the follicles occurs and the exudate in the crypts is fibrinous. It may then closely simulate a false membrane. If there is any doubt whatever, a culture should be taken, and if positive, should be accepted at its face value, regardless of the clinical developments of twenty-four hours. On the other hand a negative culture should have no influence in determining treatment if clinical appearances point strongly to diphtheria. A second culture should be taken; and any case still suspicious enough to require this should be given antitoxin without waiting for the report on the second culture.

TREATMENT.—If the case is seen during the first twenty-four hours the abortive treatment should be tried. This consists in painting over the surface of the tonsils a 50 per cent. solution of nitrate of silver. It may be applied with a cotton tipped applicator, great care being taken that the cotton contains no excess of the solution which may run over the surrounding mucosa and into the larynx. Spasm of the larynx from this cause may be very disquieting. The solution should be applied over the entire tonsillar surface. This treatment has been highly recommended, and complete control over the majority of cases within twenty-four hours has been claimed. The milder cases are undoubtedly much benefited and the course of the disease shortened by this measure. I have not seen any surprising results from its use in the more severe cases. A hot gargle of the hyposulphite of soda (one teaspoonful to a half pint of hot water) relieves the discomfort in the throat and

may be used frequently. The bicarbonate of soda may be used in place of the hyposulphite. I have been in the habit of substituting for the gargle a hot irrigation of the same solution used in a fountain syringe. The patient holds his head over a basin and plays the stream into the pharynx. The irrigation may be continued much longer than a gargle and with less fatigue to the patient. The stream comes in intimate contact with the tonsillar surfaces, washes away the exudate, opens the mouths of the crypts and promotes drainage and resolution in the tonsil. The heat also tends to allay the pain. An ice bag or cold compresses may be applied externally. It is doubtful if internal medication has any marked influence on the disease. The bowels should be freely opened with calomel followed by a saline cathartic. A ten grain Dover's powder may be given early. Guaiacum, in the form of the tincture or tablets, and the salicylates are of value, at least in allaying pain. They should be given in full doses in cases in which there is a rheumatic history. Small repeated doses of the tincture of aconite are recommended in children. Iron, quinine and strychnia are indicated during convalescence, as anæmia and debility may be pronounced.

In the recurrent cases complete removal of the tonsils during an interval of quiescence should be advised. In the majority of instances complete relief from subsequent attacks is gained. Occasionally after a tonsillectomy the nodules on the posterior pharyngeal wall and in the lateral folds enlarge and become the seat of periodic inflammation.

Septic Sore Throat.—It is often difficult to make a distinction between the sporadic and the epidemic forms of acute tonsillitis, a given case being assigned to one or the other group because of the presence or absence of an unusual number of similar cases. The disease under consideration here is quite distinct from ordinary follicular

tonsillitis, whether epidemic or sporadic, being not so much a tonsillitis as an infection involving the tissues of the pharynx generally; though undoubtedly the lymphoid nodules are the weak points in the mucosa through which the infection enters. I have, therefore, used the term "Septic Sore Throat" because it gives a more accurate idea of the nature of the disease and the extent of the tissues involved, than any of the names usually applied to tonsillar infections.

ETIOLOGY.—The disease is of recent recognition in this country and was first brought to general attention by the Boston epidemic of 1911. In England, however, epidemics of a similar nature have been frequently reported for the past thirty years. The disease is usually milk borne. Swithinbank and Newman in 1903 reviewed the outbreaks up to that time, and came to the conclusion that "it is safe to assume that a year never goes by in which there are not outbreaks of sore throat or tonsillitis due to milk or cream." The Boston and Chicago epidemics were traced directly to this source. In some instances inflammatory disease of the udder has been found among cows supplying milk to the region in which the epidemic occurs. In others the milk is infected through the medium of dairy employees with tonsillitis. The contagiousness of the infection by direct contact or through some intermediary other than milk, varies. In the Boston epidemic the disease was practically noncontagious in this sense. Yet the milk supply that caused it was probably contaminated, directly or indirectly, by organisms which had caused a protracted epidemic of sore throat in the region from which the milk came, which epidemic was not milk borne and was undoubtedly spread by direct or indirect contact. The clinical characteristics of the cases in both epidemics were similar. Growth in the milk must have modified the organism sufficiently to cause this change in its power of transmission from one individual to

another. When the infection is milk borne the epidemic appears suddenly, is largely confined to households that use the milk in question, lasts a few days and as suddenly subsides. Epidemics in which the disease is contagious by contact develop slowly, show no marked concentration, may last for weeks and subside slowly. The disease is caused by a streptococcus. Davis,[1] in a study of the Chicago epidemic, found an encapsulated streptococcus both in the throat and in the distant secondary lesions, which in cultural and morphological characteristics lies midway between the Streptococcus pyogenes and the Streptococcus mucosus. Four strains examined by him obtained from patients during the Boston epidemic showed an identical organism. Luetscher,[2] examined cultures taken from secondary lesions in five cases from the Baltimore epidemic and found in all streptococci of the hemolytic or pyogenes group. Until the classification of the various forms of streptococci has been put on a more definite and uniform basis, it seems best to consider this organism as a modified Streptococcus pyogenes of a peculiarly virulent type.

PATHOLOGY.—The inflammatory process is not confined to the tonsils and the other lymphoid nodules of the pharynx but includes the general mucosa of the pharynx and palate. The lesions start in the lymphoid tissue, however, and in some instances do not spread beyond them. There is not such a tendency to cryptic exudate as in the follicular form. On the other hand the inflammation is often sufficiently intense to cause a fibrinous exudate on the surface of the tonsils or even on the pharyngeal mucosa. The throat lesions bear a close resemblance to those of scarlet fever, and the surface exudate may easily be mistaken for a diphtheritic membrane. Secondary lesions are common in the cervical

1 Jour. Amer. Med. Assn., June 15, 1912.
2 Jour. Amer. Med. Assn., Sept., 14, 1912.

glands, in the joints, heart and kidneys, in the lungs, and particularly in the peritoneum. Peritonsillar abscess is common. The pathologic histology of the acute condition in the tonsils has not, for obvious reasons, been investigated.

Symptoms.—The subjective symptoms are not unlike those of a severe case of follicular tonsillitis. The muscular pains and the prostration are more pronounced, and there may be severe headache and even nausea and vomiting. The pulse may be high, but in many instances a relative slowing occurs. At the start the whole pharynx is congested and looks much like a scarlet fever throat. Follicular exudate soon appears; or more commonly the exudate forms diphtheria-like patches on the tonsils or the pharyngeal wall. The tonsils may be enormously swollen and edema of the surrounding soft parts may be great. Infection of the cervical glands almost constantly occurs accompanied by marked tenderness and lameness in the muscles of the neck. The glands often do not suppurate but form indefinite brawny swellings which subside slowly. Swallowing is very painful. The symptoms subside after three or four days—in mild cases without secondary complications. Convalescence is often slow.

Complications.—The complications of the disease are numerous and serious. This applies particularly to persons past middle life, among whom the mortality from secondary infections is great. Of the forty-eight deaths attributed to the Boston epidemic, two-thirds occurred at ages above fifty-five, and one-third at ages above seventy-five.[1] Children usually escape the more serious sequelæ of the disease. Peritonsillar abscess and suppuration of the cervical glands are frequent. Rarely deep-seated cervical suppuration (Ludwig's angina) takes place. Otitis media

1 Winslow, C. E. A.: Tonsillitis and an Infected Milk Supply. Jour. of Infec. Diseases, Vol. 10, 1912.

does not occur as often as might be expected, only slightly over 3 percent. of the cases analyzed by Capps [1] in the Chicago epidemic having this lesion. Multiple arthritis is perhaps the most common of all the complications. Nephritis and endocarditis are often seen. The tissues of the larynx and epiglottis may become involved. Bronchopneumonia, general septicæmia and general peritonitis are the most frequent causes of death.

DIAGNOSIS.—The disease is even more likely to be confounded with diphtheria than the usual follicular tonsillitis. The same rules hold here, however, as in that affection, and there is little excuse for a mistake, with a bacteriological laboratory at our disposal. Between acute septic sore throat and scarlet fever, on the other hand, there is grave danger of a mistake in diagnosis. All of these cases should receive a careful examination for a scarlatinal rash, both on the first day and on the two succeeding days. In no other way can this mistake be avoided.

TREATMENT.—In the less severe cases the treatment does not differ from that of the usual follicular tonsillitis. In those cases in which sepsis is a pronounced feature the autogenous vaccines should be tried; or the antistreptococcic serum may be given, the dose being 20 c.c., repeated as circumstances seem to warrant.

Acute Suppurative Tonsillitis.—Suppuration in the tonsils frequently occurs in acute tonsillitis in the form of multiple minute abscesses in the follicles. The more severe the inflammatory process the more likely is suppuration to occur. Owing to the friable nature of the tissue and the close proximity of the follicles to the crypts, these abscesses never attain a size that may be appreciated clinically. They discharge early into the nearest crypt. One can only surmise from the character of the exudate at the

[1] Jour. Amer. Med. Assn., June 15, 1912.

mouths of the crypts whether or not suppuration has taken place. The appearance of the tonsil does not help in this matter nor is the question a vital one. I have never seen an acute abscess of the tonsil that reached a size sufficient to change the clinical picture of acute tonsillitis. Suppuration in the tonsil has quite generally been confounded with peritonsillar abscess and the symptoms of the two conditions described as similar or identical. Nothing could be further from the truth. Suppuration in the tonsil produces multiple small abscesses which practically always break into an adjacent crypt and not on the surface. They are never closely confined since they are always situated near the cryptic surface and the friability of the lymphoid tissue allows them easily to break in that direction. They never, therefore, cause any of the distressing symptoms that pus under pressure produces. The symptoms described in the following paragraphs on peritonsillar abscess are those of suppuration in a confined space bounded by fairly unyielding tissues. Whenever these symptoms are present one may be certain that the pus is in the peritonsillar space and not in the tonsil itself. Suppurative tonsillitis is simply an incident of acute follicular tonsillitis, septic sore throat or the septic conditions accompanying scarlet fever or diphtheria. It requires no special surgical treatment. Occasionally a dilated crypt becomes the seat of an acute local infection. Such a focus simulates closely abscess formation since the retained debris of the crypt becomes partially liquified. The symptoms are those of mild soreness and swelling distinctly localized at some one point in the tonsil. Simple incision gives prompt relief.

Peritonsillar Abscess (Quinsy Sore Throat).—Peritonsillar abscess is a collection of pus in the peritonsillar space. In uncomplicated cases the pus always is confined between the capsule of the tonsil and the muscular walls of the

sinus tonsillaris. When suppuration occurs in this space the capsule is lifted from its bed in the sinus by the accumulating pus, and the tonsil is dislocated inward. The extent and direction of this dislocation varies with the situation and size of the abscess, which may occupy but a small part of the space, being confined by inflammatory adhesions to that part in which it originates; or the pus may burrow between the capsule and the sinus walls until the abscess cavity comprises the whole space except the inferior third, where the intimate connection of the capsule with the superior constrictor limits its extent in that direction. If the abscess is small and posterior, the posterior pillar will be pushed backward and the tonsil forward and inward. Anterior abscesses appear prominently under the upper part of the anterior pillar, and throw the tonsil backward and inward. Localization of this sort is comparatively rare, by far the greater number of abscesses comprising pretty much all of the upper two thirds of the peritonsillar space. The tonsil is then dislocated inward and slightly downward, the lower pole being more or less fixed in position by its attachment to the external wall. The abscess swelling then appears prominently in the palate and at the upper half of the anterior pillar. When it is remembered that the buried tonsil—the type most frequently associated with peritonsillar abscess—mounds high into the palate, and that the capsule covers the whole of this palatal portion, it will be appreciated that these abscesses are largely palatal, and that the capsular covering of the supratonsillar fossa is the only tissue between them and that fossa. This relationship is of importance from the standpoint of surgical treatment and will be referred to again in that connection.

Etiology.—The suppuration may be secondary to acute infections in the tonsil, especially those of the epidemic

LANE LIBRARY, STANFORD UNIVERSITY

form. More often it is independent of such infections. The same conditions that bring about recurrent acute tonsillitis—cryptic retention, chronic suppuration and fibrous hypertrophy—favor its occurrence. The infecting organism is the Streptococcus pyogenes. A large proportion of these abscesses occur in young adults. They are not common in children and are rare in infants, though I have seen two cases under ten months old. They occur at all seasons but are particularly common during the late winter and early spring months. Attacks are apt to be recurrent.

Symptoms.—The symptoms are largely due to the accumulation of pus under pressure. They come on gradually with pain in one side of the throat, which is much intensified when the patient tries to swallow. As the pus increases in amount the tension in the abscess cavity becomes greater, and by the third day—sometimes sooner—the typical picture of quinsy is presented. The head is held rigidly and is thrown slightly forward and towards the affected side. The collar is discarded to avoid pressure on the neck. The face is serious, eyes intent, lips slightly parted over tightly set jaws, between which there is often a constant drooling of ropy tenacious saliva. There is great difficulty and pain in swallowing, the pain radiating to the ear of the affected side. The jaws can be separated only slightly since such movement increases the tension in the abscess cavity and the muscles of mastication are set to avoid this. One may safely predict the size of the abscess by this symptom alone; the two are directly proportionate. The general symptoms are not severe. The temperature is usually below 100°. Examination of the throat is difficult on account of the impossibility of opening the mouth widely. The fauces are filled with a thick mucus, and there are marked swelling, redness and edema of the palate and uvula, against which the tonsil

on the affected side is thrown. The median raphe of the palate inclines to the well side,—a phenomenon that is not present in simple swelling of the tonsil. This is a minor detail in cases with other prominent symptoms; but when the abscess cavity is small and the symptoms and signs slight, it may serve to differentiate peritonsillar suppuration from inflammatory swelling of the tonsil. The swelling of the abscess, the edema of the surrounding soft parts and the protrusion of the tonsil may nearly fill the fauces. If the abscess is palatal the swelling is most prominent over the upper half of the anterior pillar and the palate. This is the most common form. Those that are confined to the outer wall of the sinus produce a prominence of the anterior pillar by pushing the tonsil inward and forward. Occasionally the abscess points posterior to the tonsil.

Duration.—When not terminated by surgical measures, a spontaneous rupture may occur at any time after the fifth day. This usually takes place through the anterior or the supratonsillar fossa where the abscess wall is thinnest. It has been commonly thought that pus does not form until after the third day. This is a mistake and means that, under the old measures, pus was seldom found until after that time because the abscess cavity had not attained a size sufficient to make its location evident. These inflammations are suppurative early. I have found the pus at the end of thirty-six hours. Untreated cases may last from two to three weeks and may even become chronic with intermittent discharge of pus.

Complications.—The abscess may break into the pharyngo-maxillary space. In this event the vessels of the carotid sheath seldom suffer as they are further protected by the stylo-pharyngeus and stylo-glossus muscles which separate the anterior and posterior parts of this space. Ulceration of these vessels with fatal hemorrhage may oc-

cur, however. Thrombophlebitis has been reported. Intermittent hemorrhage, probably due to ulceration of one of the larger vessels in the sinus walls, rarely occurs. In one of my cases the sensation of fullness in the throat was followed by a sudden burst of blood with complete relief for the time. Examination after these explosions never revealed the source of the hemorrhage. The patient recovered after having several such attacks at intervals of a few days. Similar cases resulting fatally have been reported.[1] Edema of the glottis may occur.

TREATMENT.—The patient seldom applies for treatment until after the process is well advanced and the discomfort great. Surgical evacuation of the pus is the only treatment that is of any real benefit, all other measures being of use only to allay the pain and discomfort or to hasten the suppurative process. For the former cold applications to the neck or hot alkaline gargles or irrigations may be serviceable. At the earliest possible moment the abscess should be opened and thoroughly drained. If it is small and pointing definitely at the anterior or posterior pillar, it may be opened at its most prominent point with a long sharp-pointed scalpel. Cocaine (4 per cent.) should first be injected at the site of the proposed incision; but a perfectly sharp knife is as essential as the cocaine to diminish the pain, which may be caused quite as much by the pressure of the knife on the tense abscess wall as by the incision through the tissue. In the typical abscess of the palatal type the classical incision has been through the palate, halfway between the root of the uvula and the top of the anterior pillar. This incision usually reaches the pus, but it is always very painful on account of its depth. A simpler way is to make the incision directly up through the

1 Newcomb, J. E.: Transactions American Laryngological Assn., 1908. (A résumé of the literature on this subject.)

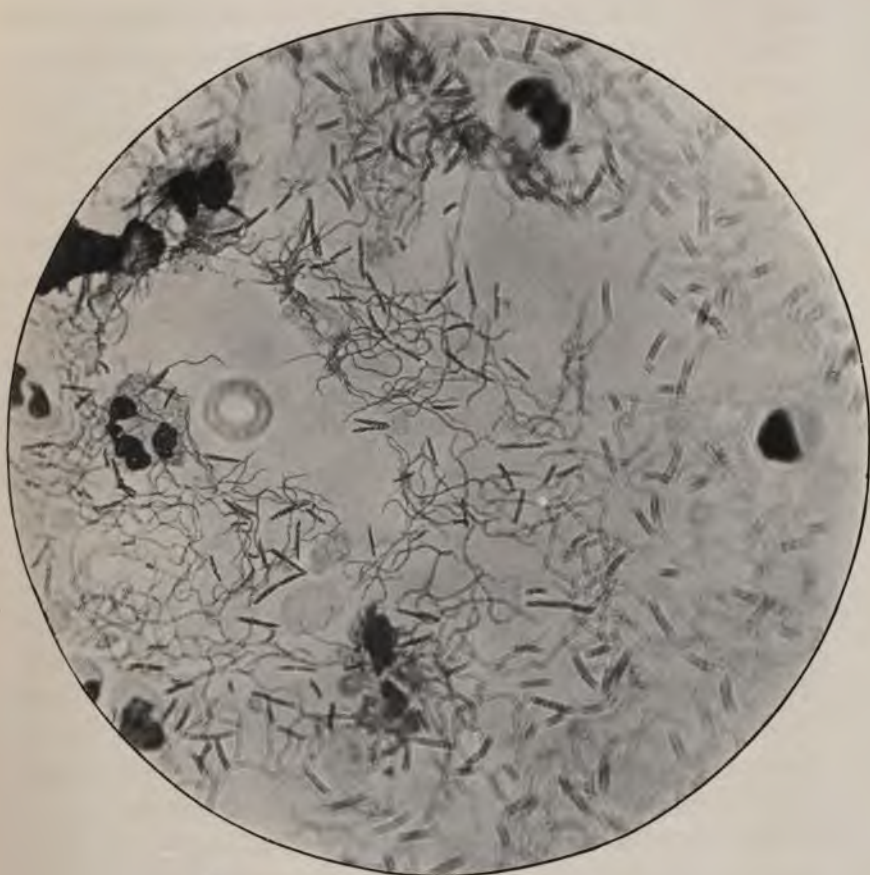

Fig. 22.

The organisms of Vincent's angina. At the periphery of the field the organisms are not in focus.

roof of the supratonsillar fossa. A right-angle sickle-knife may be used and has only to pass through a very thin layer of mucosa to reach the abscess cavity. Frequently any and all incisions fail to locate the pus, and for this reason the dissection method as advocated by Ballenger is the best for a majority of the cases. This consists in making an incision through the anterior layer of the plica exactly as though one were doing a dissection enucleation and then dissecting around the capsule until the pus cavity is reached. This is best done under local cocaine anesthesia; or ether may be given, care being taken when the pus is evacuated and the abscess cavity drained that the head is immediately thrown forward so that none of the pus is inhaled. In several cases I have removed the tonsil after thoroughly evacuating the pus. Although no ill results followed I am not inclined to advise this procedure because of the possibility of pulmonary infection.

Vincent's Angina.—Vincent's angina is an ulceration of the mucosa characterized by the formation of a necrotic membrane and the presence of the Bacillus fusiformis and a spirillum in the lesions in preponderating numbers. The ulceration is confined to one or both tonsils in a large majority of the cases, though the mucous surfaces of the mouth are often involved. Rarely the lesions are primary in the pharynx, larynx, trachea or bronchi. The ulceration is usually superficial, but occasionally the deeper structures are invaded and more or less of the entire tonsil may slough away; or it may spread to the surrounding tissues, and the faucial pillars, the palate and the pharyngeal walls become the seat of a destructive gangrenous necrosis.

Bacteriology.—The fusiform bacillus and its accompanying spirillum were first described by Miller in 1883, who found them in normal mouths and especially in cases of neglected teeth. Their presence in the lesions of ulcero-

membranous angina was first reported by Rauchfus ten years later. In the same year (1893) Babes found them in the gums of scurvy. Plaut in 1894 and Vincent in 1896 reported cases of ulcero-membranous angina associated with these organisms, and Vincent's subsequent work has given his name to the disease. The organisms have been found in all sorts of necrotic and suppurative processes, —among others hip abscess, suppurative otitis media and mastoiditis, abscesses of the spleen, lungs and liver, noma, pyorrhœa alveolaris and necrosis of the jaw. Invasion of the blood stream with consequent general pyæmia or septicæmia has been reported.[1]

The Bacillus fusiformis is an anaërobic organism and therefore does not appear in cultures grown from the lesions. The typical form seen in smears direct from the lesions is a double pointed bacillus, somewhat swollen in the middle and often presenting a beaded or barred appearance due to a varying number of deeply stained granules in its protoplasm, which is elsewhere but lightly stained. It is non-motile and decolorizes by Gram. In anaërobic cultures its morphology is very variable. Some of its forms are sinuous and when granules are absent simulate a loosely wound spirochæte. The typical spirochætal forms seen in smears do not appear in pure cultures of the bacillus.[2] The spirillum which always accompanies the bacillus is a cork-screw-like organism not unlike the Spirochæta palada, but with fewer twists and wider spirals than the latter, and when seen under dark field illumination is more rapid in its rotary movement. Both the spirillum and the bacillus stain well with carbol-fuchsin or with Unna's polychrome methylene blue. They are regarded

1 Larson, W. P. and Barron, M.: Jour. of Infec. Diseases, Nov., 1913.
Rosenow, E. C. and Tunnicliffe, Ruth: Jour. of Infec. Diseases, Jan., 1912.
2 Place, E. H.: Boston Med. and Surg. Jour., Nov. 9, 1911

by some observers [1] as different forms of the same organism, but this identity is denied by others.[2] Their causal relationship to the disease is by no means proved, as beyond the fact that they are constant in the lesions and may be cultivated outside the body, they do not fulfill the postulates of Koch. Inoculation experiments have been inconclusive. Nevertheless the consensus of present opinion supports the view that the lesions of ulcero-membranous angina are caused by the invasion of the tissues by these organisms. Although they are often found in other ulcerative lesions of the mouth and throat, such as diphtheria and syphilis, they are never seen in such vast numbers as in the smears from the anginas of the Vincent type.

ETIOLOGY.—Lowered resistance, either from general causes, or local, and following acute or chronic inflammations of the mucosa, probably plays an important part. Careless hygiene of the mouth, particularly when carious teeth or pyorrhœa are present, predispose to the disease by keeping up a constant and large supply of the organisms. Both the latter causes probably account for the large number of cases that occur in institutions for children. Its more serious forms are often secondary to other infections, as diphtheria, scarlet fever or measles; or one of the essential blood diseases may be present. It occurs most often in children and young adults, though no age is exempt. It is said to be mildly contagious but instances of direct transmission from one person to another are rare.

PATHOLOGY.—The lesion consists of a necrosis of the tissue which forms a pseudo-membrane covering a sharply defined ulceration. The membrane is of a pultaceous granular consistency and when removed exposes a bleeding surface

1 Tunnicliffe, Ruth: Jour. of Infec. Diseases, Vol. 3, 1906, p. 148.
2 Krumwiede, C. Jr. and Pratt, Josephine S.: Jour. of Infec. Diseases, Nov., 1913.

beneath. The Bacillus fusiformis and its accompanying spirillum are always present in vast numbers both in the membrane and in the advancing line of necrosis in the tissue. The ulceration is commonly superficial, healing taking place without scarring. Sometimes it is deep and destructive and is followed by marked cicatrices. The tonsils are the usual site of the disease but other parts of the mucosa of the respiratory or upper alimentary tracts may be involved.

Symptoms.—The subjective symptoms are slight, other than the soreness of the throat and pain on swallowing. There may be mild malaise. The temperature is raised but slightly or not at all. A bad taste in the mouth and fetor of the breath are always present. Objectively two general types may be distinguished, one closely simulating diphtheria and the other resembling the lesions of syphilis. In the first type there is a single membranous area on one or both tonsils. The membrane may be white, whitish-gray, gray, yellow or even of a greenish tinge. It may extend beyond the tonsils to the surface of the pillars or the palate. It is easily removed and quickly re-forms. The exposed ulcerated surface is exquisitely painful, sensitive and bleeds easily. In the second type several small discrete ulcerations may be seen on the tonsils with normal tissue intervening. The ulcers are covered by the characteristic membrane and simulate the mucous patch or the later ulcerations of syphilis according to their depth. Mild ulcerations of the buccal surfaces or gums of the ordinary aphthous type are present in many cases. The submaxillary and cervical glands may be slightly enlarged but are seldom tender.

The graver forms of the disease are comparatively rare and follow in the wake of other infections such as scarlet fever, diphtheria and measles, or occur in the course of

pernicious anæmia or leukæmia. Under these conditions the tissues are unable at times to resist the inroads of organisms which are ordinarily harmless or which make but little headway when the general resistance is anywhere near par. Large areas of the mouth and pharynx become involved and the necrosis extends deeply. The pulse is rapid and feeble and the prostration extreme. Even here the temperature is normal or only slightly raised. The submaxillary and cervical glands may be markedly enlarged. These cases usually terminate fatally.

Diagnosis.—Those cases simulating diphtheria can be differentiated from it only by smears taken directly from the lesions and by the usual cultures for the Klebs-Loeffler bacillus. The organisms of Vincent's angina are anaërobic and therefore do not appear in ordinary cultures. If the smears show them in large numbers the lesion is probably Vincent's angina. As these organisms are sometimes found in diphtheritic membranes, the cultures should be found negative for the diphtheria bacillus before the diagnosis is definitely decided. In the forms simulating syphilis, the history and the Wassermann reaction, together with smears from the lesions, make the diagnosis clear.

Prognosis.—The course of the disease is variable. In the majority of the cases the ulcers remain superficial and heal in a few days without scarring. They may, however, last for weeks. If the ulceration is deep, scarring is the rule. Recurrence is common. Those cases accompanied by very extensive necrosis are likely to prove fatal, death resulting from exhaustion or secondary septic complications.

Treatment.—Oral cleanliness is the *sine qua non* of the treatment of this affection. As long as carious teeth or suppurative conditions of the gums or tooth roots are ignored, the local treatment of the ulcers may be without

result. A good dentist is the best therapeutic measure that can be prescribed. Orthoform may be given for the pain. The general health should receive attention. Locally chromic acid (5 per cent.), zinc sulphate (5 per cent.), silver nitrate (10 per cent.), tincture of iodine or trichloracetic acid may be used. When the ulcerations are small the trichloracetic acid is very useful applied every other day. The milder solutions are better for the larger surfaces. Before making any of these applications the membrane should be gently removed with a cotton tipped applicator dipped in peroxide of hydrogen and the ulcerated surface made insensible with a 10 percent. solution of cocaine. The treatment of the severe cases is unsatisfactory. Salvarsan has been suggested and is well worth trying.

Chronic Tonsillitis.—The term "chronic tonsillitis" may be used to cover several distinct pathological conditions in the tonsils. Inasmuch as they are all the direct result of recurrent attacks of acute inflammation or of chronic infection in the crypts, they are grouped together here under this head. The most usual condition found is that of excessive accumulation of debris in the crypts *(chronic cryptic tonsillitis)*. We have already shown that practically all tonsils have a certain amount of cheesy detritus in the crypts and that this condition cannot be considered abnormal unless the material is retained for a sufficient length of time or in large enough amounts to become a focus of infection or a source of annoyance by reason of its decomposition. The conditions that favor such accumulation have been explained in the section on general pathology (p. 63).

SYMPTOMS.—Often the only symptoms are the appearance of yellowish plugs in the mouths of the crypts and the disagreeable odor that they impart to the breath. From time to time some of the material is dislodged and is

coughed out by the patient. Acute inflammation may arise around one of these plugs, which causes localized soreness that subsides when the offending plug is removed. A chronic low grade inflammation of the tonsillar parenchyma may be present accompanied by mild soreness of the throat which varies in intensity from day to day and is subject to frequent subacute exacerbations. Beyond this soreness the patient may experience no discomfort. On the other hand such tonsils are often the source of chronic toxæmia or of localized infections in the joints, heart or kidneys.

Marked chronic retention in the crypts may exist without giving rise to any symptoms, subjective or objective; nor can the most painstaking examination with the probe or with pressure with a flat instrument in the anterior fossa be depended upon to demonstrate it. The reason is that no pressure can be brought to bear on the blind ends of the crypts near the capsule, where the worst conditions of decomposition and bacterial accumulation are prone to occur. In cases of distant infections suspected to be of tonsillar origin, I know of no way of determining with certainty the non-existence of such foci until the tonsils are taken out and examined in sections. I have dwelt carefully elsewhere on the arguments for and against tonsil enucleation for the relief of systemic infections, and have here only to suggest again that, while the tonsils are always to be regarded with suspicion, they should never be condemned without a careful examination of the patient for other possible sources of infection.

Chronic Suppurative Tonsillitis.—Chronic abscess formation in the parenchyma of the tonsil is not uncommon. These abscesses are usually small and are situated just under the capsular surface more often than elsewhere. Occasionally they may be seen under the surface epithelium. Their contents may be sterile; or the streptococcus, pneu-

mococcus or staphylococcus may be recovered from the pus. They usually produce no local symptoms, but have an important bearing on the question of systemic infections of tonsillar origin. Unless they are superficial, they produce no gross changes that may be seen until after the tonsils have been removed.

Cyst of the Tonsil.—Cyst of the tonsil results from an inflammatory occlusion of the mouth of a crypt and the subsequent dilatation of the resultant blind sac by the accumulation of cheesy detritus. It may be situated anywhere in the tonsil and when small is easily confounded with the chronic abscess. Cysts occasionally attain great size. One that I removed seemed to have absorbed the whole tonsil. On section, however, it was found that a considerable amount of lymphoid tissue remained between the cyst wall and the capsule. Such cysts are lined with epithelium, rather thin but compact, beneath which there may be fibrous or lymphoid tissue, according to the extent of regressive change in the tonsil. They produce no symptoms unless large enough to cause sensations of fullness in the throat.

Calculus of the Tonsil.—If the detritus from the crypts of the tonsil is rolled between the fingers a gritty calcareous consistency is sometimes found. This calcareous deposit may become so pronounced as to form a definite calculus in the crypt. Calculi of very considerable size have been found, one reported by Robertson measuring 1¾ x 1½ inches. They may be multiple. If small they cause no symptoms. Larger calculi may produce discomfort or even pain on swallowing, and the sensation of a foreign body in the throat. If not too large they may be removed through the mouth of the crypt, which may have to be enlarged with the right-angle knife before the delivery can be made. Local cocaine anesthesia is sufficient.

TREATMENT OF CHRONIC TONSILLITIS.—Tonsillotomy or the removal of as much of the detritus as is possible from the crypts and the emptying of such abscesses or cysts as may be seen, will sometimes give temporary relief. Recurrence is almost sure to occur, however, and it will usually be found that such temporizing methods are a waste of time. Tonsillectomy is always to be advised. It promises complete and permanent relief, since by it all of the crypts are removed with their surrounding diseased lymphoid tissue.

Hyperkeratosis Tonsillaris.—Hyperkeratosis of the tonsil is a condition of the epithelium of the crypts in which its more superficial cells, instead of being cast off from its surface, accumulate there in more or less thick horny layers. The process is analogous to callous formations of the skin. It sometimes extends slightly beyond the mouths of the crypts over the external epithelium, but such extension is usually limited to the immediate neighborhood of the crypt. It never occurs in a physiologically active tonsil, but is confined to those that are in a regressive stage. It is therefore most commonly seen in young people from the sixteenth to the twentieth year. It tends to disappear spontaneously.

ETIOLOGY.—In order to understand the etiology of this condition we must revert briefly to the character of the epithelium of the crypts, and the changes that take place in its structure with age. The cryptic epithelium appears in the embryo in the form of solid buds which push their way into the subepithelial fibrous tissue of the sinus tonsillaris and around which a diffuse infiltration of lymphoid tissue takes place. Hollow crypts are soon formed from the solid buds by a keratosis of their central cells, which separate from the deeper cells and form horny cores that are discharged into the faucial cavity. The cryptic epithe-

lium is at this time like that of the surface,—stratified squamous, many cells in thickness, and with a definite basal outline indented by numerous fibrous papillæ. With the appearance of the follicles in the lymphoid tissue this basal outline becomes obscured, the active and rapidly growing lymphoid tissue invading the epithelium and disintegrating its deeper layers, so that they either disappear or are seen only as loose aggregations of cells extending from the surface into the lymphoid tissue in the form of isolated and ragged fragments. Only a very thin epithelial tissue is left intact covering the surface of the crypts. Like stratified squamous epithelium elsewhere, it is in a state of active growth in its deeper layers, the cells of which are gradually pushed towards the surface. As they approach this point they become more and more flattened, lose their nuclei and are finally cast off as dead cells into the cavity of the crypt. These exfoliated cells might easily form keratoid masses under the irritating influence of retained debris and bacterial toxins, much as keratosis of the buccal and lingual surfaces sometimes occurs with the irritation produced by tobacco smoke. That this does not occur in the active tonsil of childhood is likely due to the outpouring of lymphocytes through the epithelium, which carries the effete epithelial cells away from the surface. With the beginning of regressive changes in the tonsil, however, the conditions are changed so that keratosis of the cryptic surface may and often does take place. The germinal centers of the follicles become less active, fewer lymphocytes are produced and in consequence there occurs a recession of lymphoid cells both from the fibrous reticulum of the tonsil and from the epithelium of the crypts, the isolated fragments of which are allowed to fall together and again to form a compact stratified tissue of considerable thickness, approaching the surface type of epithelium. Under these con-

Fig. 23.

Hyperkeratosis of the tonsil. The mouth of a crypt with projecting plug of keratoid material.

Fig. 24.

Hyperkeratosis of the tonsil, showing the compact character of the cryptic epithelium, from which the keratoid mass has been partially detached at the upper left quadrant of the figure.

ditions the dead superficial cells show a decided tendency to accumulate in the form of more or less frayed horny plates, being no longer lifted from the surface by the active migration of the lymphocytes. This tendency is very common during retrograde metamorphosis of the tonsil, but is usually so slight as to be unrecognizable clinically. Often, however, the keratoid accumulation is so extensive as to fill the crypt with a white horny core which protrudes from its faucial opening. (Hyperkeratosis.) Why the process should be so marked in some tonsils and slight in others, or what the conditions are that cause it to decline gradually, are questions that cannot as yet be answered.

The process was formerly thought to be a mycosis (pharyngomycosis) inasmuch as the leptothrix was found abundantly both on the surface of the horny plugs and between their frayed layers. That these organisms are in no way a cause of the condition but are present simply as saprophytes, is now generally conceded.

Pathology.—The histological changes in the tonsil of hyperkeratosis are those of retrograde metamorphosis, i. e., reduction in the number and size of the follicles and in the relative size of the germinal centers; and, secondary to these changes, a partial recession of lymphocytes from the fibrous reticulum and from the cryptic epithelium. There results an increase in the relative amount of fibrous tissue, even when no actual hyperplasia of this tissue takes place. There may be a distinct fibrous mucosa, free from lymphocytes, under the epithelium of the crypts, which has reverted to the surface or infantile type. These changes are in no way pathological and are seen in all regressive tonsils. Keratosis may occur over a varying area of the surface of the individual crypt. It may be limited to the deeper parts or to one side, while again the whole crypt may be involved. In sections stained with eosine-methy-

lene blue the keratoid areas show a compact epithelium rather thinner than that of the surface but with a definite line of demarcation between it and the fibrous or lymphoid tissue beneath. No fibrous papillæ extend into the epithelium. Between the epithelium and the keratoid mass the line of demarcation is almost equally plain, as the protoplasm of the live cells has a purplish hue while the horny material takes the eosine stain deeply. If the keratosis involves only a limited area, the remainder of the epithelium of the crypt will be found to be much thicker but less compact than the keratoid portion. It is usually infiltrated with lymphocytes but is seldom so disintegrated as the epithelium of the tonsil of the child. If the process is general, the horny material fills the cavity of the crypt and protrudes from its faucial opening. It is disposed in concentric layers which are frequently loosened one from the other so that they become somewhat broken and frayed. Bacteria are numerous in the interstices.

Hyperkeratosis occurs most frequently in the crypts of the faucial and lingual tonsils. Occasionally those of the nodules of the posterior and lateral pharyngeal walls are involved. I have never seen the condition in the adenoid of the vault though I am not prepared to say that it may not occur there. The character of the epithelium of the crypts of these latter nodules would seem to preclude the possibility of its occurrence.

Symptoms.—On examination the characteristic chalky-white plugs are seen in the mouths of the crypts. On the pharyngeal walls they are of minute size but are much larger in the faucial and lingual tonsils where the crypts may be widely dilated by the keratosed material. They are difficult to dislodge and are firm and resistant to the touch. They usually cause no subjective symptoms, unless the plugs protrude far enough to rub against some neighbor-



Fig. 25.

Latent tuberculosis of the tonsil. The tubercles show as light areas in which giant cells are frequently present.

ing mucous surface, when cough and the sensation of a foreign body in the throat result. Those of the lingual tonsil are especially apt to cause this by contact with the tip of the epiglottis. The affection can scarcely be confounded with any other because of the character of the plugs and the entire absence of local or constitutional symptoms.

TREATMENT.—The patient usually requires no treatment other than the assurance that the condition is absolutely harmless and that in all probability it will disappear within a year or two. If any of the plugs cause irritation, the protruding part may be removed with a small amount of the surrounding tissue.

Diphtheria.—A general consideration of diphtheria is not within the scope of a treatise on the tonsils. The disease belongs rather to the domain of internal medicine than to that of the specialist. The differential diagnosis between it and the tonsillar diseases for which it is likely to be mistaken has been given in the several sections dealing with those diseases. The relation of the tonsils to diphtheria carriers is discussed in conjunction with the question of post-operative diphtheria (p. 158).

Tuberculosis of the Tonsils.—Tuberculosis of the tonsils may be primary or secondary. The first is latent in character, producing no surface lesions and no local symptoms other than those of hypertrophy. The latent tubercular tonsil is by no means always large, however. It is therefore difficult if not impossible to make a diagnosis of the condition except in those cases in which tuberculosis of the cervical lymph glands is present, and then only by inference. The lesions are usually found accidentally after the removal of the tonsils. They consist of discrete or confluent tubercles made up of epithelioid cells among which giant cells are conspicuous. There is seldom round-cell

infiltration and never, so far as my experience goes, any evidence of caseation; which accounts for the absence of surface ulceration. Though this tissue always produces experimental tuberculosis in animals, I have never been able to demonstrate tubercle bacilli in the stained sections. The bacilli probably gain entrance through the attenuated epithelium of the crypts, whence they may pass through the tonsillar parenchyma without producing lesions and find lodgment in the cervical lymph glands. Many cases of tuberculosis of these glands undoubtedly arise in this way, whether primary tubercles are or are not formed in the tonsils. The adenoid of the pharyngeal vault is presumably another source of such infection, as it has been proved, both histologically and experimentally, that this tissue is frequently a focus of latent tuberculosis. The incidence of this form of the disease in the faucial tonsils is about 6 per cent. of all cases examined; and, according to Lartigan and Nicoll, somewhat higher (10 per cent.) in the pharyngeal tonsil.

The relation of the tonsils and other lymphoid nodules of the pharynx to tubercular disease of the cervical glands and of the pulmonary apices has been discussed (p. 75).

Secondary tuberculosis occurs in the tonsils as a result of infection either from the sputum in advanced pulmonary disease or through the blood stream, as in acute miliary tuberculosis. Such infection must be common inasmuch as Strassman found it in thirteen of twenty-one tuberculous cadavers and similar results were reported later by Krueckman. That a majority of such cases are of the masked variety, however, and produce no surface lesions, is evident when one considers the comparative rarity of the diagnosis during life.

Clinically the lesions of secondary tuberculosis of the tonsils consist of a tuberculoma without ulceration, or of

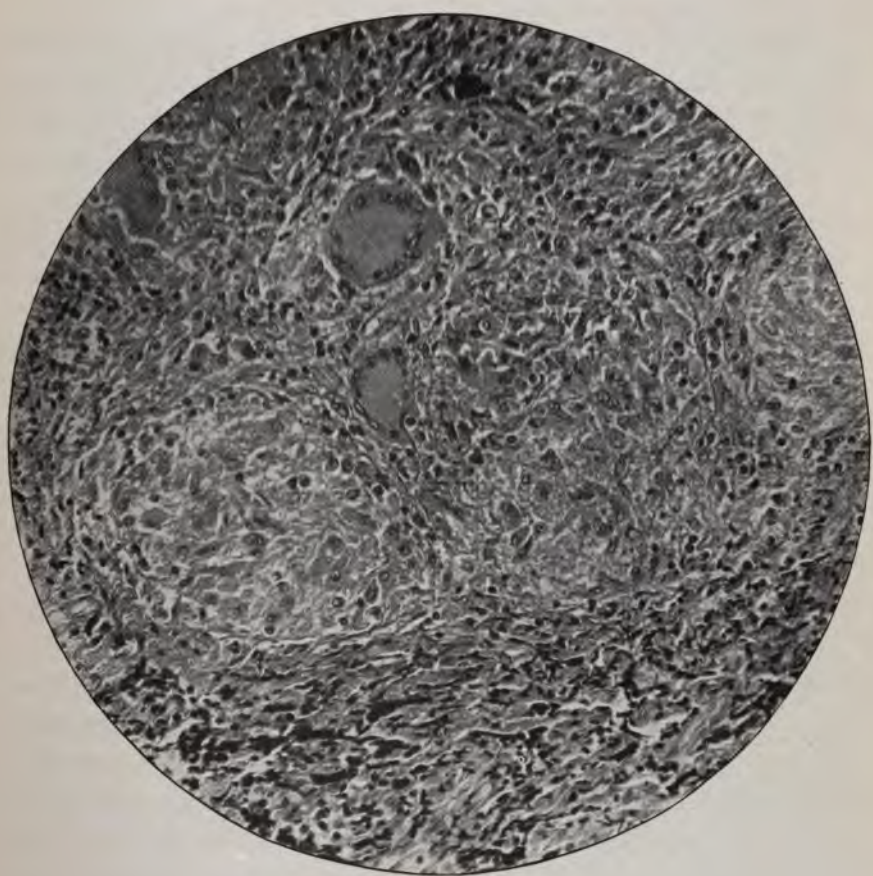

Fig. 26.

Field from Fig. 24, showing the histology of the tubercle. There are two large giant cells slightly above the center of the figure.

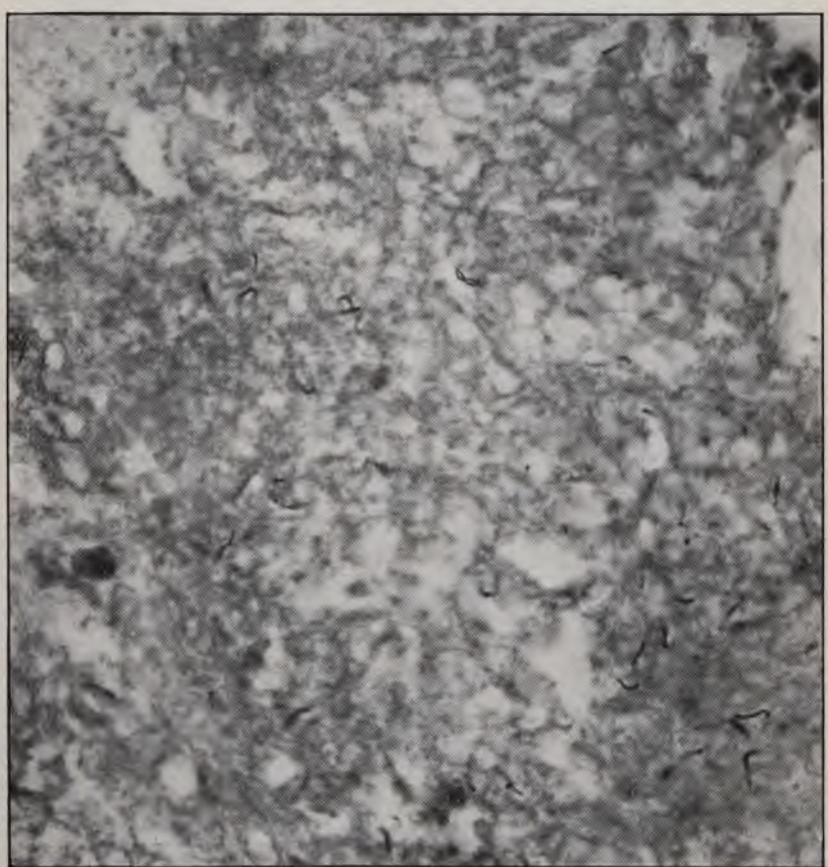

Fig. 27.

Active tuberculosis of the tonsil, showing the tubercle bacilli. The lymphoid tissue has disappeared, the whole tonsil being converted into a mass of epithelioid cells.

single or multiple ulcerations of the surface. I have seen one example of the former, occurring in a case of acute miliary tuberculosis, in which the whole tonsil was reduced to a mass of epithelioid cells with numerous small caseous foci and innumerable bacilli. (Fig. 27.) When ulceration occurs it is usually multiple and superficial, though it may be of great depth, a large part of the tonsil being destroyed by the process. The superficial ulcers have ill-defined borders, a slightly inflamed areola and are covered by a grayish-white muco-purulent secretion. They are usually very sensitive.

Diagnosis.—A diagnosis of latent tuberculosis cannot be made except by removal of the tonsils and subsequent microscopic examination. In the secondary form the existence of pulmonary or laryngeal tuberculosis together with the characteristic "worm-eaten" ulcerations are sufficient to distinguish it from syphilis, the only affection for which it is likely to be mistaken.

Prognosis.—In the latent form the prognosis is good. Secondary involvement of the cervical lymph glands often occurs. In all secondary cases the prognosis is distinctly bad owing to the pulmonary or laryngeal conditions.

Treatment.—Whenever the existence of latent tuberculosis of the tonsils is suspected because of tubercular glands in the neck, tonsillectomy should be advised. Besides removing the primary source of the infection, it seems in many cases to have a marked effect in reducing the size of the glands and on the healing of chronic sinuses of the neck that so often resist all other forms of treatment.

Secondary ulcerations should be made insensible with a 10 per cent. solution of cocaine, the surface curetted and then brushed with pure lactic acid or a 5 per cent. solution of formaldehyde. Pain should be controlled with orthoform, cocaine applications or opiates. The general treat-

ment does not differ from that of pulmonary tuberculosis.

Syphilis of the Tonsils.—The primary lesion of syphilis is said to occur more often on the tonsils than on any other part outside of the genitalia. Statistics vary widely as to its incidence but a conservative estimate would place it at about 10 per cent. of all extra-genital chancres. This frequency is difficult to explain since the tonsils are so far removed from the possibility of direct contact with syphilitic lesions, except through perverted sexual practices which can account for but a small percentage of these cases. The tonsils are not subject to trauma and unless this occurs their surface epithelium is quite sufficient to resist infection. On the other hand they are placed at the first narrowing of the alimentary tract and hastily swallowed crusts of bread and other hard foods previously contaminated might penetrate the surface at this point. Or it may be that infection takes place in the crypts, where the Spirochætæ pallidæ might remain alive for a long time or even multiply under existing conditions of warmth, moisture and protection. Their passage through the cryptic epithelium, especially if chronic inflammatory conditions were present, would be easy to understand. Chancre of the tonsil resulting from the use of unclean surgical instruments sometimes occurs. Cleanliness and asepsis should make such accidents impossible.

SYMPTOMS.—The initial symptoms may be those of an acute follicular tonsillitis. I have seen one case of this kind in which the acute symptoms subsided, leaving the patient greatly weakened and with a persistent enlargement of one tonsil, which was slightly painful, somewhat indurated and without ulceration. Cervical adenitis on the affected side was marked; but as the patient had an old scarring of the neck presumably due to tubercular adenitis, the diagnosis

of tuberculosis of the tonsil with secondary involvement of the glands was made. Tonsillectomy was advised; but before it was done the appearance of secondary skin lesions made the diagnosis evident. The tonsil is usually enlarged and presents either an eroded or ulcerated surface. The ulceration may be limited or may include pretty much all of the surface. The erosion or ulceration has a sharply cut well-defined margin and is covered with muco-purulent secretion. It bleeds easily. Pain is commonly not a prominent symptom but occasionally it is severe. Enlargement of the cervical glands is always present and constitutes a most characteristic diagnostic feature. The tonsil gland is the first to be enlarged but those under the sterno-mastoid soon follow suit so that a very considerable indefinite swelling appears in that region. The primary lesion usually lasts well into the secondary period of the disease. In some of my cases the diagnosis was made certain at the first visit by the evidence of the skin lesions.

Diagnosis.—The diagnosis is difficult. The lesion may be confounded with diphtheria, Vincent's angina, tuberculosis, tertiary specific ulcerations, carcinoma or even with peritonsillar abscess. Diphtheria could be suspected only in the beginning and if the tonsillar erosion were covered with a muco-purulent secretion. The absence of general symptoms and the Klebs-Loeffler bacillus in the cultures would eliminate it. Vincent's angina may simulate chancre of the tonsil very closely especially when it is accompanied by cervical adenitis. The absence of pain and the presence of an indurated general swelling of the tonsil would suggest chancre. Examination of smears from the ulcer would demonstrate the presence of the Spirochæta pallida or the fusiform bacillus with its associated spirillum. Tuberculosis and tertiary specific ulceration may be eliminated by the history, the character of the ulceration and the absence

of adenitis. The Wassermann reaction would farther distinguish primary from tertiary lesions, at least during the first few weeks, as the reaction seldom appears before the fifth week of the chancre. Carcinoma could be mistaken only in its very early stages and even then the absence of glandular enlargement, and the age of the patient would be suggestive. Microscopic examination of a piece of excised tissue would settle the diagnosis. It seems hardly possible that chancre of the tonsil should ever be mistaken for peritonsillar abscess; yet if the chancre shows simply as an enlarged and but slightly eroded tonsil with slight redness and swelling of the faucial pillars, it may simulate peritonsillar inflammation of limited extent. The duration, the adenitis and the absence of the deflection of the median raphé of the palate, which is a constant sign in peritonsillar abscess, should lead to an examination of smears for the Treponema pallidum.

Secondary Syphilis of the tonsils occurs in conjunction with the lesions of the palate and faucial arches, though they often are not involved in the early symmetrical erythema of these parts. Mucous patches may be multiple and discrete, resembling the exudate of follicular tonsillitis; or they may coalesce so as to form a continuous patch covering the tonsil and extending over the faucial pillars and palate. The appearance of these patches varies; the epithelium may be greatly thickened so that they show as pulpy-white or yellowish-white surfaces, elevated and with sharply defined edges, and somewhat resembling wet blotting paper. These may be mistaken for diphtheria. The epithelium again may be only slightly thickened so that the surface has a frosted or opalescent appearance which may be so slight as to escape the notice of any but a careful observer. The tonsils may become greatly hypertrophied, sometimes with the formation of the diffuse mucous patch and sometimes without

any change on the surface whatever. Superficial ulceration of the tonsillar surfaces is sometimes seen in secondary syphilis. The ulcers are apt to be symmetrically placed on the tonsils, are small and have grayish-white ill-defined borders. They are usually quite sensitive.

Tertiary Syphilis of the tonsils occurs in the form of gummatous infiltration which usually breaks down early and forms deep, irregular and sharply-defined ulcers covered with yellowish muco-purulent secretion. Before the ulcerative stage gumma of the tonsil may be mistaken for a neoplasm. The Wassermann reaction and later the examination of a piece of excised tissue will prevent confusion.

Treatment.—Local treatment of specific throat lesions is almost never called for, as constitutional treatment, especially salvarsan, controls the lesions perfectly. Nowhere are the magic effects of this drug seen to better advantage than in the treatment of the lesions of the mucosæ, which clear up with incredible rapidity after its use. The iodide of potassium and mercury are of course useful adjuncts; and while they may not be necessary to gain control of local lesions, they should be used today in the general treatment of syphilis with the same degree of thoroughness and for the same length of time as was customary before salvarsan made its appearance.

Diseases of the Lingual Tonsil.

The lingual tonsil is subject to the same diseases as the faucial tonsils. Owing to the small size of the nodules, however, and the consequent shallowness of their crypts, infectious processes are not so frequently seen here and are usually of mild degree.

Hypertrophy of the lingual tonsil is seldom seen in children but is fairly frequent in adults, especially in females.

It gives rise to no symptoms, unless the nodules are large enough to come in contact with surrounding tissues, when the sensation of a foreign body in the throat and an irritative cough may be present. The point of contact is nearly always the tip of the epiglottis. The treatment consists in reducing the size of the nodules. This may be done with the snare if the mass is sufficiently prominent. The larger flat nodules are more easily removed with the lingual tonsillotome; or they may be gradually reduced by the galvano-cautery.

Acute Lingual Tonsillitis differs in no way from the same process in the faucial tonsils and often accompanies the latter condition. The treatment of the two is identical (See p. 82).

Chronic retention in the crypts rarely occurs in the lingual tonsil for very obvious reasons of freedom of drainage. These nodules are not important, therefore, from the standpoint of systemic infections. Hyperkeratosis, on the other hand, frequently occurs, and is productive of contact symptoms more often than the same condition in the other lymphoid nodules of the throat. The offending nodules should be removed.

Abscess formation beneath the capsule sometimes takes place. It is analogous to peritonsillar abscess. It is usually limited to one side. The symptoms are pain and tenderness referred to the region of the great cornu of the hyoid bone. Marked swelling and redness may be seen at the base of the tongue on the affected side. Free incision is the only effective treatment, though hot alkaline gargles or irrigations may be given to relieve the pain in the early stages.

An accessory thyroid gland in this region is sometimes mistaken for hypertrophy of one of the lingual nodules. When present it is situated in the central line at the site of

the foramen cæcum which is somewhat anterior to the lingual tonsil. It is always sessile and covered with normal epithelium. Care should be taken to make sure of the presence of the normal thyroid before removing the gland at the base of the tongue.

The lymphoid nodules of the posterior and lateral pharyngeal walls and also those of the vault (the pharyngeal tonsil) are often involved in acute inflammations of the tonsils. They require no special descriptions. The chronic changes in the latter nodules that bring about the condition known as "adenoids" are described in the section on that subject. It only remains to mention briefly certain chronic conditions of the posterior and lateral nodules. (For their anatomy and histology, see p. 52.) They often become hypertrophied without causing symptoms. This is especially true in children and adolescence after the removal of the faucial and pharyngeal tonsils. Such hypertrophy may be considered normal. Aside from this vicarious hypertrophy the etiology of their enlargement is that previously described in connection with the tonsils (p. 47).

Occasionally these nodules become the seat of a chronic infection with secondary involvement of the cervical glands, the joints or the heart. More often they cause no trouble or are the distinctive feature of the local condition known as chronic granular pharyngitis. Suppuration may occur beneath the fibrous mucosa of the lateral folds and is to be differentiated from peritonsillar abscess by the location of the swelling, which is behind the posterior pillar.

TREATMENT.—They often require no treatment. If symptoms of chronic pharyngitis are present the local use of the galvano-cautery or the silver nitrate bead is of service. Only two or three nodules should be cauterized at one sitting. Of much greater importance is the treatment

of chronic conditions of the nose and naso-pharynx. The accessory sinuses should be carefully investigated. Any constitutional diathesis such as rheumatism, gout, syphilis, etc., should receive appropriate treatment.

CHAPTER VII.

DISEASES OF THE PHARYNGEAL TONSIL. (ADENOIDS.)

The anatomy and histology of the lymphoid nodules of the naso-pharynx have been described (p. 52). They are normally present in all children from birth to puberty, at which time they usually undergo regression and disappear. They often, however, persist into adult life. They are not in themselves pathological, though this conception of them is unfortunately not confined to the laity. While they are subject to most of the morbid changes that take place in the faucial tonsils and cause with extraordinary frequency the symptoms first described by Wilhelm Meyer of Copenhagen in 1868, they are often present, even in a fair degree of development, without causing any symptoms whatever. This is especially true of the central adenoid that does not fill the fossæ of Rosenmüller and is situated in a relatively large naso-pharynx. I make these statements with no wish to underestimate the pathological significance that these nodules often assume, but merely as a mild protest against the assumption that they are always pathological and that therefore they should always be removed. If this were true, the operation of adenectomy would be almost universal.

Etiology.—The pharyngeal tonsil becomes hypertrophied under much the same conditions as the faucial tonsils (p. 47). The two do not always become enlarged together however. While it is rather rare to find any considerable hypertrophy of the latter without finding at the same time

a large adenoid, the absence of tonsillar enlargement cannot be depended upon as a sign that the adenoid is small. These nodules may become hypertrophied during the early weeks of infancy, though the majority of cases occur between the third and the tenth years. Heredity seems sometimes to be a factor, as it is not uncommon to find several children in the same family affected. The acute infections of childhood such as measles, scarlet fever and diphtheria, are often followed by hypertrophy of this tissue. Repeated attacks of acute rhinitis and adenoids go hand in hand, each playing the rôles both of cause and effect in a species of vicious circle.

PATHOLOGY.—The pharyngeal tonsil may become pathological in three ways: first, by a chronic catarrhal inflammation similar to that described in the faucial tonsils; second, by their situation, which may be such that they interfere with the free drainage of the Eustachian tubes; and third, by hypertrophy, so that they obstruct nasal breathing. It is not always easy to distinguish between these different forms clinically, nor is such a distinction of any great practical value. It is, however, important to recognize that the first two forms may produce pathological changes in the middle ears that are of serious consequence to the patient when no other symptoms are present than a slight and perhaps intermittent difficulty in hearing. These changes are brought about by direct extension of the chronic inflammation to the mucosa of the Eustachian tubes and the middle ears, which results in chronic thickening and opacity of the tympanic membranes. Retraction of the membranes is always present in greater or less degree, due to poor drainage and the gradual absorption of the air in the tympanic cavities. Acute purulent otitis media may occur because of the retention of inflammatory secretions. It is almost sure to arise in these cases during the course

of any of the acute infections of the pharynx, such as Streptococcus tonsillitis, diphtheria and scarlet fever. The hypertrophied adenoid causes much the same changes, and in addition produces obstruction to nasal breathing with all its untoward effects upon the general development of the child. The face becomes lengthened, the alæ nasi collapsed and the upper lip shortened and retracted; these changes, together with the open mouth, give the countenance an expression of stupidity so characteristic that it has been termed the *adenoid facies.* Yet it is well to remember that any form of long continued nasal obstruction will produce the same result, though adenoid hypertrophy is by far its most common cause. Deformities of the chest, especially retraction of the infra-mammary region and depression of the ensiform cartilage (pigeon-breast), are common. The high, narrow and V-shaped palatal arch which has been claimed to result from nasal obstruction is rather a cause than an effect, as the naso-pharynx in such cases is shallow and the nasal choanæ small. Under these conditions very small hypertrophies of any kind in the nose or naso-pharynx will produce nasal obstruction and this accounts for any prevalence that may exist of this type of maxilla in adenoid hypertrophy.

Symptoms.—Slight deafness may be the only symptom. It may be intermittent and for this reason is apt to be neglected. The changes in the ears depend upon the length of time that the condition has existed. The drums may be but slightly retracted though they are usually markedly so and are more or less thickened and opaque. In the obstructive form the characteristic changes in the face and chest are usually noted, unless the case is seen early. The breathing is mainly through the mouth, and whereas it may be quiet during the day, it becomes much embarrassed at night, since the tongue tends to fall back against the pal-

ate, producing snoring and the so-called suffocative "night-terrors." Chronic rhinitis with frequent acute exacerbations is the rule, and constant liability to "colds" is one of the best evidences of the presence of a chronic infectious adenoid. The secretions from the nose and naso-pharynx may be blood-stained owing to the extreme vascularity of the adenoid tissue. Bronchitis may be present, but cough is more often caused by the dropping of mucus into the naso-pharynx or by the extension of the chronic inflammation to the mucosa of the pharynx. The voice is thick and has a nasal quality as though it were situated behind the eye-brows. When the obstruction is marked certain of the consonants that require nasal resonance, as M and N, are not pronounced, B and D being substituted. In nursing infants, feeding may be seriously interfered with. Children with obstructive adenoids are prone to be backward in their mental development. Deafness partially accounts for this; but perhaps a more important element is the deficient aëration of the blood and the consequent headaches, lassitude and inability to fix the attention (Guye's "aprosexia"). Laryngismus stridulus, nocturnal enuresis, asthma, stammering and epileptic convulsions have been attributed to the presence of adenoids. Their etiological significance in such cases is at best doubtful. The pharyngeal nodules may be the primary focus of infection in chorea, rheumatic fever, endocarditis, infectious arthritis and cervical adenitis, but in this respect they are not so important as the faucial tonsils since retention in their crypts is seldom marked.

Diagnosis.—When the adenoid is small the changes in the ears and the history of recurring acute rhinitis are the surest diagnostic guides; and in any case of periodic or progressive deafness in a child with retracted ear-drums, the adenoid tissue of the vault should be thoroughly re-

moved, unless a condition anterior to the naso-pharynx can be found to account for the symptoms. In children the more pronounced obstructive type of adenoid should never give any difficulty in diagnosis, if care be taken to exclude deviation of the nasal septum (a very common thing in children) or other anterior obstruction. The adenoid may be directly demonstrated either by the post-nasal mirror or by the finger in the vault. The latter procedure is in general to be deprecated, both because it is painful to the child, occasioning a distrust that is difficult to overcome, and because the information it gives is often of so little value or may be gained in less objectionable ways. All children have some adenoid tissue unless it has previously been removed; it is therefore not remarkable that a negative diagnosis seldom results from the examination with the finger in the vault. Except when it is excessive, in which case the diagnosis may be made without an examination of the naso-pharynx, the size of the adenoid is not the important thing, but rather its relative size to that of the vault, or its freedom from chronic inflammation. The first point may be settled by the post-nasal mirror in a fair percentage of cases even in young children. When the mirror cannot be used the symptoms are a reliable guide, if other causes for them are excluded. In the adult, besides lesions in the nose, certain tumors of the naso-pharynx must be excluded.

Prognosis.—The prognosis depends upon the length of time that the condition has existed and the extent of the secondary changes that have taken place. When these are not marked the outlook is extremely good; but when the facial characteristics and chest deformities have once been acquired, or when the tympanic membranes have become much thickened and retracted or a chronic suppurative otitis media established, the parents of the child should be

made to understand thoroughly that the operation is done to prevent further harm rather than for the correction of that which has already been done. The mental sluggishness of many chronic mouth-breathers disappears in a remarkable manner after the removal of an obstructive adenoid; nevertheless, the operation is not calculated to make brilliant children out of imbeciles, and any prognosis along this line should be given with the utmost caution. The general health and vigor of the child usually changes wonderfully for the better, the amount of improvement depending of course on the extent to which the adenoid was responsible and the existence of any other causes of impairment. As to the mouth-breathing, it may persist even after the removal of all nasal obstruction, having become a habit. Usually, however, normal nasal respiration is soon established. When deviation of the septum or other anterior obstruction exists, or when the V-shaped palatal arch is marked, producing as it does narrow nares and small nasal choanæ, the prognosis in this respect should be guarded. It should always be understood that any operation on the pharyngeal tonsil for the relief of systemic infections is in the nature of an experiment, as it is much more difficult here even than in the case of the faucial tonsils, to make any positive statements. Joint and heart lesions, and especially the associated chorea, are often much benefited by the operation. The various neuroses that have been attributed to adenoids,—asthma, enuresis, epilepsy, etc.,—may also be benefited by the operation; certainly the removal of any cause of obstruction and irritation in the respiratory tract is to be advised in asthma, and is sometimes followed by relief, more or less complete. But the etiology of these neuroses is so obscure and the failure to obtain any results from operation so frequent, that no hope of improvement should be given beyond what might

naturally be expected as a result of improvement in the general condition of the patient.

TREATMENT.—If the pharyngeal tonsil causes no symptoms it may be disregarded, even when it is of a size that may easily be demonstrated. There is one exception to this rule. When for any reason the faucial tonsils are removed, the nodules of the naso-pharynx should be removed at the same time. In adults, if the tonsillectomy is done under local anesthesia, this may not be important; but in children the liability of the pharyngeal nodules to hypertrophy after tonsillectomy makes this procedure the safe one, as it adds nothing to the severity of the operation and may save the criticism that is sure to be made if the adenoid should give rise to trouble later. The converse of this rule is not so obvious, as tonsillectomy is too serious an operation to undertake without adequate cause, and should never be done simply because the patient is under ether. Future tonsillar symptoms may of course arise, and the operator may then be blamed for not doing a complete operation at the first sitting. Nevertheless, I believe that the surgeon should not be influenced by this possibility and that the results in the vast majority of cases will prove the soundness of this position.

Whenever the pharyngeal nodules give rise to any of the symptoms described, they should be removed thoroughly and as early as possible. Temporizing is always dangerous; and the practice of waiting for an adenoid to atrophy cannot be condemned too severely, as irreparable damage may be done before this takes place. In infants and very young children the operation may be done under light ether anesthesia. In older children ether or nitrous oxide may be used. In adults local anesthesia is satisfactory and may be produced by simply brushing the surface with a 10 per cent. solution of cocaine. The upright position as in tonsillectomy

is best suited for all cases, infants and very young children being held in the arms of a nurse. The main mass of the adenoid in the central line may be removed with the Gottstein or the Boeckmann curette or the Schuetz or the La Force adenotome. The latter instrument has the advantage of holding the severed tissue in a closed box so that there is no danger of a piece of adenoid dropping into the larynx. The solid cutting blade also makes it the best of instruments when the central adenoid is tough and fibrous. When the curette is used it is introduced behind the soft palate and then brought forward until its broad extremity touches the upper part of the vomer. With moderate pressure upward and backward the handle of the instrument is then raised so that the cutting edge of the curette sweeps the superior and posterior walls of the naso-pharynx. Care should be taken that the curette is in the central line before this movement is made, in order to avoid the possibility of wounding the Eustachian eminences. If a considerable amount of adenoid tissue remains, the curette should again be introduced, and the movement repeated. The nodules of the superior and posterior surfaces are effectively removed in this way. Personally I prefer the La Force adenotome for this part of the operation, as it makes a clean cut and usually takes all of the central mass without undue traumatism of the underlying fibrous mucosa. After the central nodules have been removed, those of the fossæ of Rosenmüller remain to be dealt with. I know of no instrument at all comparable to the index finger for this purpose. It is an intelligent curette that is very effective in clearing the fossæ of their friable lymphoid tissue without doing any injury to the Eustachian eminences. The objection that the finger is an unsurgical instrument is true only when the operator fails to observe the ordinary rules of surgical cleanliness. The operation by direct inspec-

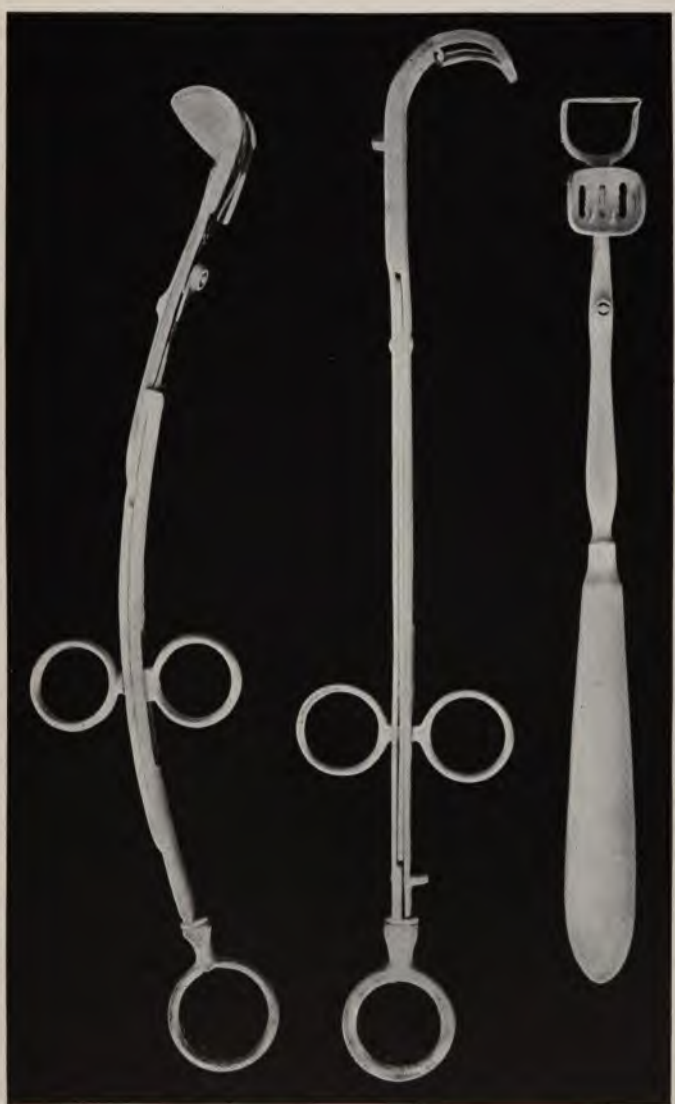

Fig. 28.

A group of adenoid instruments. From left to right—the La Force adenotome, the Schuetz adenotome and the Boeckmann curette.

tion has recently been advocated and may be done through the Yankauer speculum, the lymphoid tissue being removed piece-meal with the tonsil ring-punch. The method has no advantages over the older ones. There is little to be said about post-operative treatment. The patient should be kept quiet for twenty-four hours and given nothing but cold soft foods. The usual diet may be resumed much earlier than after tonsillectomy. Acute otitis media occasionally follows adenoid operations. With this exception complications are extremely rare.

The question is often raised as to the regeneration of the pharyngeal nodules after their removal. It is anatomically possible for such regeneration to occur, because it is impossible to remove all of the lymphoid tissue of the naso-pharynx without removing the whole mucosa. Obviously this is not desirable when so large a surface is concerned. As a matter of fact the deep fibrous mucosa should always be left intact; and in this tissue regeneration of lymphoid nodules may take place. One occasionally sees this even after careful and thorough operations. Nevertheless it is the exception to the rule.

Thornwaldt's Disease.—Acute inflammation of the pharyngeal tonsil occurs both in conjunction with that of the other nodules of Waldeyer's ring and independently of it. During these attacks adhesions may form between the contiguous surfaces of the units of the central mass and one of the longitudinal clefts converted into a canal. The central cleft is the one usually affected. This canal may become the seat of a chronic suppurative process with constant discharge of purulent material. The symptoms are those of chronic pharyngitis. Removal of the adenoid with the La Force adenotome very promptly cures the condition.

CHAPTER VIII.

NEOPLASMS OF THE TONSILS.

Neoplasms of the tonsils may be *benign* or *malignant*. The former remain localized indefinitely, do not invade the surrounding tissues and do not form metastases. They usually grow slowly and seldom or never ulcerate. Malignant neoplasms, on the other hand, grow more rapidly and tend to invade neighboring tissues by direct extension and to form metastases in distant parts by extension through the blood or lymph streams.

Benign Neoplasms.—Benign neoplasms of the tonsils include the papilloma, fibroma, lipoma, angioma and fibro-enchondroma. The papilloma and the fibroma are by far the most common though they are not so often seen here as in other parts of the fauces and pharynx. The lipoma, angioma and fibro-enchondroma are only rarely reported. The latter may arise from the cartilaginous nodules that are not infrequently found in the capsule and the fibrous trabeculæ. *Papilloma* springs from the surface mucosa and consists of branching fibrous stalks surrounded by thickened epithelium. The line of demarcation between the two tissues is always perfectly distinct, wherein the growth differs from the malignant epithelioma (carcinoma) in which the epithelium invades the lymph spaces of the underlying fibrous tissue. The multiplication of the fibrous stalks produces numerous cauliflower projections springing from a common base. The growths are therefore commonly pedunculated. They may be single or multiple. Sessile papillomata with cauliflower surfaces are less often seen on the tonsils. They may simulate closely the warty

epithelioma. Whenever such a growth occurs in a person over forty years of age, malignancy should be suspected, and a piece of tissue removed for microscopic examination. Papilloma is said to undergo occasionally malignant changes. *Fibroma* of the tonsil is a hard, rounded, smooth tumor, usually single, and may be sessile or pedunculated. It is much less vascular than the naso-pharyngeal fibroma. It occurs during adolescence or young adult life. It ulcerates rarely and is of slow growth. Lipoma and enchondroma present no gross appearances that serve to differentiate them from the fibroma. The diagnosis can be made only with the aid of the microscope. *Angioma* is easily recognized by its purple, nodular surface and its soft, almost fluctuating consistency, composed as it is of tortuous blood vessels or blood sinuses supported by a delicate fibrous framework.

Treatment of Benign Tumors.—The single pedunculated papilloma may be removed with a snare and the base cauterized with the electro-cautery. The application of a 10 per cent. solution of cocaine gives sufficient anesthesia. A better method is to dissect the growth with a sharp scalpel, including all of the stump and a small amount of the surrounding tissue. The sessile form may be treated in the same way; but if much tissue has to be removed a tonsillectomy will prove more satisfactory. *Angioma* presents some difficulties in treatment because of the dangers of hemorrhage. For this reason electrolysis is to be preferred to the electro-cautery snare. Treatment should be repeated once or twice a week until the growth is obliterated. Other benign neoplasms need not be removed unless their size causes discomfort or obstruction. In that event removal of the tonsil as described under tonsillectomy is indicated.

Malignant Neoplasms.—These include both the carcinoma and the sarcoma. The former occurs in advanced

life,—very rarely before the fortieth year and in the majority of cases after the fiftieth year. Cases have been reported in young people. Sarcoma on the other hand, though it has a predilection for the young or middle aged, may occur at any time of life. *Carcinoma* occurs more frequently in males than in females. It may be primary in the tonsil; usually, however, it is secondary and invades the tonsil by direct extension from the base of the tongue or from the faucial pillars. In its early stages the growth shows an infiltrated area which soon breaks down in the center, forming an ulcer with slightly raised edges and an uneven surface covered with muco-purulent material. The ulcer extends in all directions by the formation of new nodules at the periphery and the breaking down of old ones. The rate of growth varies within wide limits. In the middle-aged and robust it is rapid while in old people it often seems to partake of the low vitality of the individual. I have seen a carcinoma of the tonsil in a man of seventy years that had existed three years without producing any extensive destruction of tissue and with only slight glandular involvement. The cervical glands usually enlarge early, however. The symptoms of carcinoma are ulceration, pain which may be severe and lancinating in character, often shooting to the ear on the affected side, loss of weight, cachexia and early involvement of the cervical glands. The last symptom, together with the age of the patient, usually suggest the correct diagnosis. If the cervical glands are not enlarged, syphilitic ulceration may easily be confounded with carcinoma. The history, the therapeutic test, the Wassermann reaction and finally the microscopic examination of a piece of excised tissue serve to differentiate the two. The papillomatous form of carcinoma may be mistaken for a simple papilloma, and malignancy should always be thought of whenever such a growth ap-

pears in a person of forty years or over. The microscope will clear up all doubts in the matter. *Sarcoma* of the tonsil arises from the cells of its fibrous supporting framework, and according to the character of the tumor cells is called spindle-cell sarcoma or round-cell sarcoma. Certain of these tumors in which the formation of giant cells is a conspicuous feature are called giant-cell sarcoma. The distinction between the fibroma and the fibro-sarcoma is not always easy to make, even by the microscope. The presence of mitotic figures in the cells of the tumor indicates sarcoma. The so-called lympho-sarcoma (lymphoblastoma) arises from the lymphoblasts of the germinal centers of the lymph follicles. It may be primary in the tonsil or it may be secondary to such growth in the lymphatic glands of the neck (Hodgkin's disease). Occasionally it is involved in the general course of a lymphatic leukæmia, which is a circulating metastasis of the lymphoblastoma. Clinically the sarcoma may simulate fibroma if the growth is slow. Rapidly growing sarcoma has a somewhat soft consistency and may give the sensation as of fluctuation. It does not ulcerate early and may remain localized and encapsulated for a considerable period of time. It spreads by extension to the deep tissues behind the angle of the jaw. Lympho-sarcoma may appear as a definite tumor or as a more or less uniform infiltration. It is apt to show astonishing vagaries in its growth. It ulcerates much earlier than the sarcoma; but the ulceration may heal and the growth diminish for a time or even completely disappear.

Treatment of Malignant Tumors.—The treatment of malignant tumors of the tonsils is thorough extirpation if the patient is seen early and before glandular involvement or extensive infiltration of surrounding tissues has taken place. The prognosis is not hopeful. In advanced stages palliative treatment alone is warranted.

CHAPTER IX.

SURGERY OF THE TONSILS.

The Choice of Operations.

Up to within the last eight years the operation universally done on the tonsils, either on account of hypertrophy or diseased conditions, consisted in the removal of those portions only that protruded beyond the faucial pillars, —the so-called tonsillotomy. With the increase in knowledge of the anatomy and the pathology of the organs, this partial operation has to a large extent been superseded, at least in this country, by the radical operation of tonsillectomy, by which is meant the complete removal of the tonsil in capsule. The change is one of the greatest of the advances that have been made in recent years in the surgery of the nose and throat. Nevertheless, it has met with great opposition in certain quarters, largely because of the mystery that appears to surround the question of the function of the organs. I have already touched upon this point in the section on that subject, but wish again to emphasize the views there expressed, viz., that the tonsils are important physiological tissues during childhood; that they should never be removed without adequate cause; but that when such cause exists, their function is either permanently impaired or is easily taken up by the other lymphoid tissues. There should, therefore, be no hesitation on that score in totally removing diseased tonsils.

Operations on the tonsils, other than those for malignant disease, are done for one of two objects,—either to reduce their size or to relieve conditions brought about by the

absorption of bacteria or the toxic products of their growth from the crypts. If reduction in size is the only object, tonsillotomy is a perfectly satisfactory operation in those cases in which the tonsils are pedunculated and project far beyond the faucial pillars. Indeed, in many such cases a tonsillectomy is unwittingly done by the advocate of the less radical operation. But in those cases in which the hypertrophied tonsil is buried and mounds high into the soft palate, so small an amount of tissue is removed by a tonsillotomy as to be of little service in relieving symptoms due to the size of the organs. A regeneration of lymphoid tissue often occurs after these partial operations so that within a short time the tonsils may be as large as ever. On the other hand, regeneration after a well done tonsillectomy is an impossibility, since all of the tissue elements from which the lymphoid tissue is developed are removed from the sinus tonsillaris. It is as reasonable to expect a regeneration of a finger nail after the matrix has been cut away as to look for a recurrence of tonsillar tissue after a tonsillectomy. Cases of apparent regrowth are due either to the mounding of a hypertrophied lateral nodule of the lingual tonsil into the sinus tonsillaris, or to imperfect removal of the inferior or the superior pole of the tonsil.

Tonsillotomy is entirely inadequate in those cases in which the symptoms depend upon absorption from the crypts. The reasons are obvious. Debris and its accompanying bacterial growth are most noticeable at the blind end of the crypts. Chronic abscess formation and tubercular foci of the latent type are most often found near the capsular surface. This region is not affected in the slightest degree either by a tonsillotomy or by the still milder operations of galvano-cautery applications to the crypts or of slitting the crypts with the right-angle knife. Sometimes temporary relief follows these measures, due to

the removal of the more superficial plugs in the crypts. But it will usually be found that the symptoms recur, and often with increased severity, since the conditions of retention in the deeper parts of the tonsil may be rendered more pronounced by adhesions and cicatricial contractions at the mouths of the crypts. The failure of these mild measures is perhaps nowhere more evident than in cases of cervical adenitis. I have repeatedly seen patients who showed no improvement in the cervical condition following tonsillotomy but in whom the glandular enlargement promptly subsided after enucleation.

Tonsillotomy.

Indication.—The only indication for tonsillotomy is prominence of the tonsil in the fauces, with no other symptoms than those due to such prominence. Even in these cases a tonsillectomy should be advised unless the tonsil is placed in a shallow sinus that does not extend into the soft palate.

Technique.—Local anesthesia is to be preferred in the adult. In children general anesthesia should be the rule. The child is held in the upright position by an assistant and facing a good light. A mouth-gag is placed in the side opposite the tonsil to be operated on, the tongue depressed with a tongue depressor, and the tonsillotome placed so that the tonsil engages the aperture. The instrument is then pressed outward and closed when as much as possible of the tonsil has been pressed through the ring. The head should be brought forward and the handle of the instrument carried outward just as the pedicle is cut through so as to insure the delivery of the tonsil through the mouth. If the tonsil is pedunculated it will be removed in capsule by this method. If a large portion remains, a punch may be used to still further reduce its size. In the

adult the technique is the same except that, as local anesthesia is used, no mouth-gag is necessary.

Tonsillectomy.

Indications.—1. Simple Hypertrophy.—A mild degree of hypertrophy cannot be considered abnormal, and unless symptoms of obstruction to breathing, interference with the voice and the flexibility of the palate, or aural complications due to pressure are present, is not an indication for the operation. One exception to this rule may be noted. When the tonsils are placed in a shallow sinus so that the greater part of their bulk extends beyond the faucial pillars (the pedunculated tonsil), they may nearly occlude the faucial passage even when their size is not above that of the average tonsil. Under these conditions they should be removed. As we have stated before, a tonsillotomy may be done here since so great a proportion of the tonsil is included in the guillotine that the operation is practically a tonsillectomy. Hypertrophy causing aural or obstructive symptoms always calls for an enucleation.

2. Recurring Attacks of Acute Tonsillitis.—In these cases the origin of the infection should be considered. Occasional mild tonsillitis occurring in the course of infections obviously starting in other parts of the upper respiratory tract do not call for removal of the tonsils. Treatment should rather be directed to those parts primarily involved—usually the nose or naso-pharynx. If, however, these secondary inflammations of the tonsils are of great severity, a tonsillectomy is indicated. In this class of cases a complete freedom from attacks of sore throat after the operation may not be predicted with confidence, since the nodules of the posterior pharyngeal wall and lateral folds are usually involved and are likely to be affected with the same frequency as before the operation.

Indeed, these nodules often become more prominent after the removal of the tonsils—a kind of compensatory hypertrophy—and inflammatory conditions in them more noticeable. This in no way detracts from the value of the operation, as the symptoms of lateral and posterior lymphadenitis are less severe than those of tonsillitis, and is but an indication for the subsequent treatment of these nodules. It should be borne in mind, however, in giving a prognosis to the patient, who very likely will be disappointed if encouraged to the belief that he will have no more sore throats after his tonsils have been removed. If the recurring inflammations are primary in the tonsils and are obviously due to infection from the crypts, tonsillectomy is indicated even if the attacks are not severe. Chronic or subacute tonsillitis in which the soreness of the throat is slight but persistent, with frequent mild exacerbations, is a type always due to absorption from the crypts. It is these cases that most frequently show signs of systemic disturbance, with indefinite symptoms of general malaise due to the absorption of toxins, or definite infections in distant parts, notably the heart and joints, due to the entrance of organisms from the crypts into the blood stream. Here the results of tonsillectomy are very satisfactory. The patient may almost be promised freedom from the local throat symptoms, and great improvement in the joint or heart lesions even to their complete subsidence may be expected.

3. Recurring Peritonsillar Abscess.—Peritonsillar abscess is always due to streptococcus infection from the crypts. Tonsillectomy is indicated, as it not only removes the source of the infection but also obliterates the peritonsillar space so that a subsequent abscess is an anatomical impossibility.

4. Chronic Retention in the Crypts.—By this is meant

the obvious retention of debris in the crypts or the supra-tonsillar and anterior fossæ. Local or constitutional symptoms may be present but often there are no symptoms beyond a foul breath due to the decomposition of the masses in the crypts. A tonsillectomy is indicated; but it must be remembered that in some individuals the secretions of the mouth or naso-pharynx may be distinctly malodorous with no obvious reason. All other possible sources of the odor should be looked for and the question of operation and the prognosis determined by the result.

5. Cervical Adenitis.—The differential diagnosis as to the probable source of infection in this condition has been discussed in the section on the lymphatics of the tonsil. If the evidence points to the tonsils as the infecting source, they should be removed. The reduction in the size of the glands following operation is often marked and if no secondary changes have taken place in them, they usually completely subside. Even in tubercular adenitis an improvement often follows enucleation of the tonsils. I have seen two cases of chronic sinuses of the neck of long duration promptly heal after a tonsillectomy, whereas in both a previous tonsillotomy had been without result. In neither of these, however, was any material from the neck obtained for microscopic examination, so that the nature of the adenitis was not determined. The tonsils were not tubercular. Whether the existing lesions of tubercular adenitis are ever materially influenced by the removal of the source of the infection may be questioned. It is reasonable to suppose, however, that cutting off the supply of organisms tends to limit the extent of the process and the operation should always be advised with this end in view.

6. Systemic Infections.—Whenever the evidence points to the tonsils as the source of systemic infection they should be removed. They may be the atrium of infection

and yet be small and to all appearances normal. Cases without tonsillar symptoms, either objective or subjective, must be decided individually, and as a general rule the enucleation of the tonsils may be done as a purely experimental therapeutic measure when there are no other obvious foci of infection. The percentage of successes will be very materially increased if this latter precaution is always observed. The teeth and gums, the accessory sinuses of the nose, the ears, and the genito-urinary and gastro-intestinal tracts should be ruled out, so far as may be practicable, as sources of the infection. Tonsillectomy having been decided upon, the situation should be explained carefully to the patient, as in many cases no benefit follows the operation; if the operator has been too sanguine of results, the failure not only is a source of disappointment to the patient, but reflects discredit on an operation which, in well considered cases, is one of the most satisfactory in surgery.

Anesthesia.—Tonsillectomy may be done under local or general anesthesia. In children general anesthesia should always be employed, while in adults the choice rests largely with the patient and depends to a less degree on the preference of the operator. Personally I prefer general anesthesia in all cases; but if the patient for any reason objects to ether and is a person of a fair degree of self-control, local anesthesia is perfectly satisfactory.

Local Anesthesia.—Cocaine (½ per cent. solution), novocaine (½ per cent.), or the bisulphate of quinine (2 per cent.) alone or combined with the hydrochloride of urea, may be used. The operation may be started almost immediately after the injection of cocaine. Novocaine and the bisulphate of quinine require ten to fifteen minutes to produce the required degree of anesthesia but have the advantage of being non-toxic. It is necessary to use only

a small amount of these solutions, the important point being to inject them around the capsule into the peritonsillar space, and especially at the base of the tonsil, the separation of which by the snare is very painful unless thorough anesthesia is secured. A general mild anesthesia of the fauces and pharynx should first be produced by spraying a one per cent. solution of cocaine over the parts and repeating it in two or three minutes. With a hypodermic syringe having a long needle the anesthetic solution may then be injected without pain or gagging. Three or four injections may be made through the anterior pillar, beginning at the base and passing upward to the superior pole of the tonsil in the soft palate. The region of the posterior pillar is then anesthetized by three injections, the needle passing through the tonsil till the firm resistance of the capsule is felt and the injection made at this point. If cocaine is used, only two or three drops of the solution should be injected at any given point. Novocaine and the bisulphate of quinine may be used somewhat more freely. When thorough anesthesia is present the operation is done as under a general anesthetic, except that as little manipulation of the parts as possible is desirable, as the success of the operation depends largely on the freedom of the patient from gagging.

General Anesthesia.—Ether is in most cases the ideal anesthetic. It may be preceded by nitrous oxide or the nitrous oxide-oxygen mixture. Complete surgical anesthesia should be the rule in cases of dissection with the sharp knife, as with the reflexes of the pharynx still active such dissection is difficult. The operation with Sluder's guillotine may be done before the stage of complete anesthesia is reached.

The Preparation of the Patient.—The patient should be prepared as for any major surgical operation. The urine

should be examined and the condition of the heart and blood vessels ascertained. Hemophilia should be excluded as far as possible by history. A brisk cathartic should be given the evening before the operation and the lower bowel emptied by enema in the morning. No food should be taken for twelve hours before the operation. Atropia (1/120 gr.) and morphia (1/6 gr.) should be given adults one-half hour before the anesthetic is started, which diminishes the amount of secretion in the throat and for that reason makes the anesthesia run more smoothly and gives the operator a better view of the fauces. The operation should always be done in a hospital. Anyone who has had the experience of treating post-operative bleeding with none of the facilities of the hospital operating room will appreciate this precaution.

The Position of the Patient.—The Rose position, with the head over the end of the table, the side position with the head on the edge of the table, or the upright position, the patient being held in a chair by assistants, may be used according to the preference of the operator. I cannot too strongly recommend the upright position for all cases, as it gives the best possible view of the operative field and the operator may see at every moment just what he is doing as well as if he were working on the outside of the body. No other position gives this. The objections to the position are largely sectional, due to lack of familiarity with it and founded on the fear that blood may be inhaled and pulmonary complications ensue. The fear is groundless. At the Massachusetts General Hospital, where the upright position has always been used and where the number of tonsil and adenoid patients is very large, no untoward results have ever been seen that could in any way be ascribed either to the position or to the anesthetic.

The Operations.—Many methods have been devised for

Fig. 29.

The right-angle tonsil knife, the author's tonsil grasping forceps, and the peritonsillar knife for tonsil dissection.

the removal of the tonsils in capsule, among others the right-angle knife dissection, the dissection with the straight scalpel, the finger dissection, Robertson's scissors dissection and the Sluder operation with the guillotine. While satisfactory results may be obtained with any of these, I believe the combined method of dissection with the straight knife and the snare and Sluder's operation are best suited for the removal of the tonsil in capsule with the least trauma to the surrounding tissues. Sluder's operation is not adapted to those cases in which the tonsils are bound to the walls of the sinus tonsillaris by adhesions, though Sluder himself reports success in 99½ per cent. of all cases. Doubtless failure in many instances is due to imperfect technique, but the fact remains that the average operator will find difficulty in removing by this method the large fibrous tonsil of the adult, especially if the patient gives a history of previous peritonsillar abscess. In this class of cases, even if the dull guillotine is used, bleeding will occur more frequently after this operation than after the combined knife and snare dissection. On the other hand, in the average case and especially in children, the operation is the neatest and quickest that has yet been devised. Personally I always dissect tonsils with the straight scalpel and snare, for the reason that a good technique cannot be maintained if the operation is done only occasionally and a certain number of tonsils must be removed by one of the dissection methods. I prefer, therefore, to do all my tonsil operations in this way, though the operative time is much longer than that of Sluder's method.

THE COMBINED DISSECTION AND SNARE OPERATION.—The dissection with the straight knife only will be described. Both the right-angle knife and the scissors are more apt to injure the pillars, with two possible untoward results—either deformity of the palate or post-operative bleeding,

particularly from the veins of the posterior sinus wall. The chances of hemorrhage or deformity following the operation here described are reduced to a minimum.

The patient is placed in a chair in the upright position and held by an assistant. Direct daylight illumination may be sufficient; if it is not, the reflected light should be used. After the mouth-gag has been inserted, the tongue depressor is placed by the operator but is held during the succeeding steps of the operation by an assistant.

The tonsil is then grasped with a two-pronged tonsil forceps, the upper prongs entering the tonsil at the level of the floor of the supratonsillar fossa, and the lower prongs as near the base as possible. The prongs of this forceps are about a quarter of an inch apart, are long and slender, and instead of being bent at a right-angle to the shaft, form a slightly obtuse angle with it. They are easily forced deeply into the substance of the tonsil, where they engage the larger fibrous trabeculæ without macerating the more superficial friable tissue. Even in the adult tonsil these trabeculæ become much attenuated as they approach the surface, and there they offer little resistance to the pull of a tenaculum; deeper down they are much heavier and stronger. It is, therefore, of the greatest importance that the first bite of the forceps should be a deep one, especially in those cases in which previous peritonsillitis has created a network of adhesions between the capsule and the surrounding tissues. Under these circumstances the line of demarcation between the tonsil and the walls of the sinus can at times only be discerned by moving the tonsil in various directions, and it is most embarrassing to find the tenaculum constantly pulling away during this procedure. This instrument seldom tears through even the soft tonsils of childhood.

The forceps inserted, the tonsil is pulled gently forward

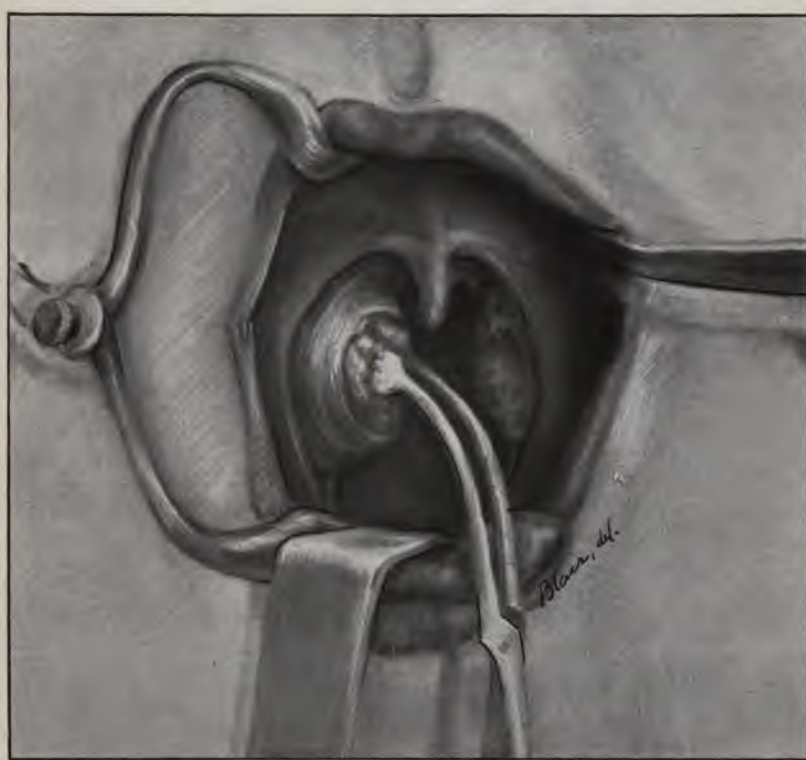

Fig. 30.

The dissection of the tonsil. First step. The tonsil is pulled forward and inward putting the plica on the stretch. The plica of this tonsil passes all the way around the organ.

Fig. 31.

The dissection of the tonsil. Second step. The incision at the internal border of the plica has been made and the gaping wound shows the glistening fibrous capsule beneath.

and inward, so that the plica is put upon the stretch and is backed up by the bulk of the tonsil. With a long, sharp-pointed knife an incision is made just outside the inner border of the plica from its base upward and backward to the point of juncture with the posterior pillar. (The word "plica" is used here to designate both the plica triangularis and the plica supratonsillaris.) This incision is carried through the anterior or faucial fold of the plica, and immediately the deep fibrous layer of the posterior fold (the capsule) is exposed. The incision opens up what may be regarded as a closed musculo-fibrous sac (the peritonsillar space), which completely surrounds the tonsil except over its faucial surface, and which extends internally as far as the internal border of the plicæ. The walls of this sac are but loosely adherent except at that point in its lower half where the larger vessels pass from the deep structures into the tonsil. This applies only to those cases in which there has been no previous peritonsillar inflammation, which may cause marked adhesions between the walls of the sac. Inflammation of the tonsil itself does not usually leave such adhesions.

A blunt dissector is now introduced into the incision, and unless adhesions are present this space may be opened up easily and the whole upper and anterior part of the tonsil turned out of its bed in the sinus tonsillaris. Slight adhesions may be broken by a more vigorous use of the dissector, but if the adhesions are marked it is better to divide them with the knife, as the too vigorous use of the dissector thoroughly bruises the tissues and a very painful throat results. The posterior pillar is not touched.

The importance of a perfectly sharp knife in making the initial incision cannot be over-accentuated; for if the knife edge be dull, all delicacy of touch is lost; the operator cuts too deeply in his efforts to cut at all, goes through both

layers of the plica and into tonsillar substance and so gets outside of the peritonsillar space, and a clean dissection of the tonsil becomes difficult if not impossible, as the line of demarcation between the capsule and the walls of the sinus cannot easily be found. This is the origin of many of the so-called adhesions of the tonsil.

The loop of a snare threaded with a No. 7 wire is now slipped over the handle of the tenaculum and then pulled down to a size that the bulk of the tonsil will just about fill. No danger of catching the uvula is then present. With gentle traction inward and forward, the tonsil is pulled into the loop, the cannula of the snare being above, and thrust downward behind the superior lobe of the tonsil as far as the dissection permits. The wire is then pulled as tight as may be, the patient's head thrown forward, and while the ether is applied for the other tonsil, the snare is slowly screwed home. This last step should be very deliberate, as it is at this time that all the larger vessels of the tonsil are divided. Two or three minutes may be taken in effecting the separation.

The bleeding after this operation is almost always slight as the initial incision with the knife touches no vessels of any size, while all of the larger vessels are divided by the wire of the snare. Often the sheet wrapped around the patient is unstained. Lest some believer in more radical surgery who dissects out his tonsils, even to the base, with a sharp knife or scissors should maintain that the entire tonsil is not removed by this method, I will say that nothing is easier of proof than the success or failure of the operation according to this standard. If the excised tonsil shows an intact capsule, then the ablation has been complete: and in the vast majority of cases such an intact capsule may be demonstrated. Even when the lower part of the tonsil is

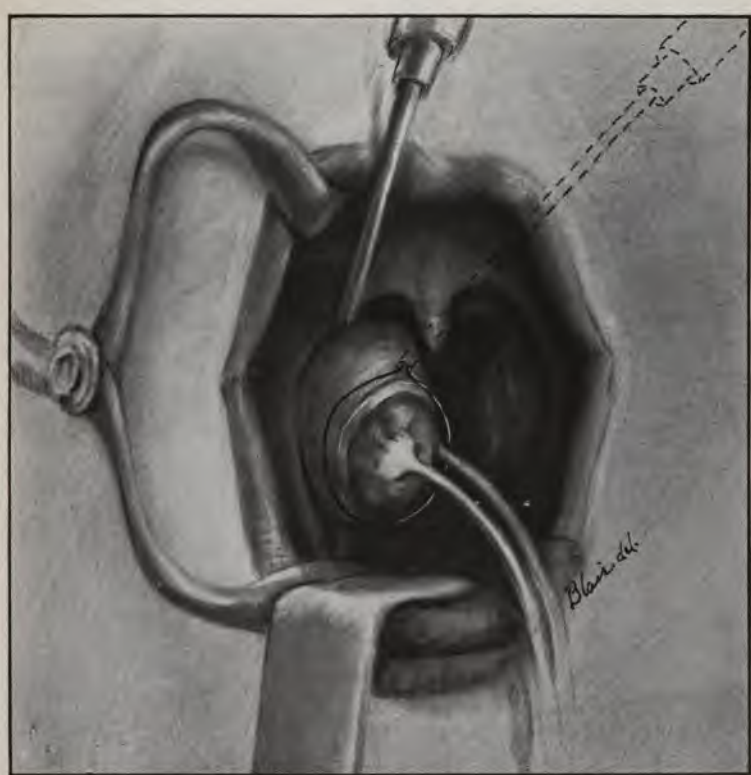

Fig. 32.

The dissection of the tonsil. Third and fourth steps. The blunt dissector has separated the whole upper part of the tonsil from the walls of the sinus tonsillaris and the snare is shown both in the act of being slipped over the tonsil and in its final position with the cannula thrust deeply behind the upper pole and the loop drawn taut.



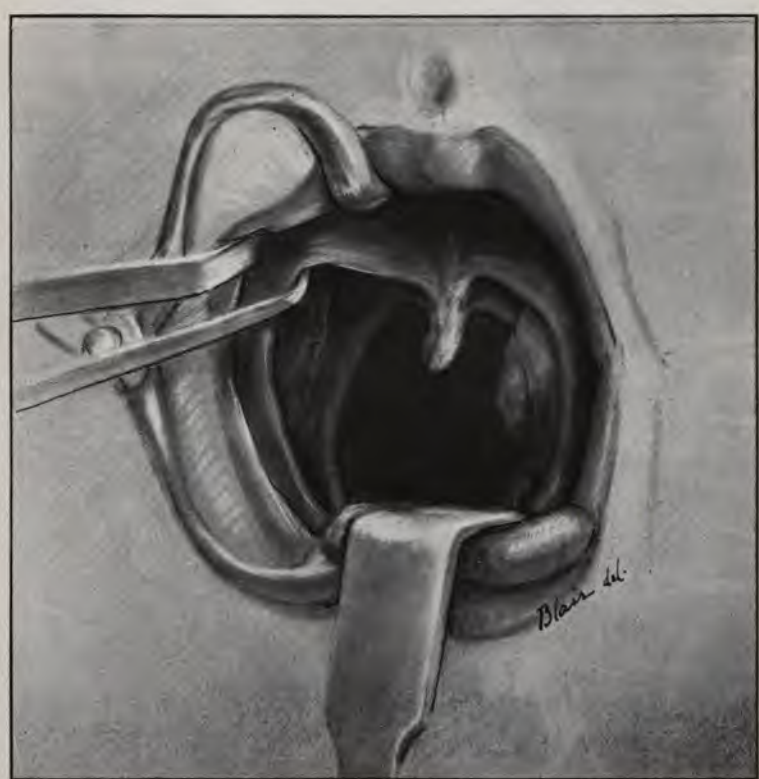

Fig. 33.

The dissection of the tonsil. The sinus tonsillaris after the tonsil has been removed. The anterior pillar is held aside in order to show the depth of the sinus and also to show the large vein in the posterior external angle.

missed, as it is occasionally by any method, it is easily removed by a second application of the snare.

Concerning the posterior pillar: I never dissect it because I think the snare does this better than any other instrument can do it. I have never seen the integrity of the posterior pillar in the slightest degree affected by the wire. This is important because it is here that the largest vein of the sinus wall lies, and if it is wounded, as it often is during sharp dissection, particularly with the right-angle knife, it may give rise to a troublesome post-operative hemorrhage.

The Finger Dissection, as advocated by Richards, is a modification of the foregoing method, the dissection of the upper part of the tonsil being accomplished with the finger instead of the knife and blunt dissector. It is desirable here to make the initial incision through the mucosa with a knife, though it is possible to carry out all the steps up to the application of the snare with the finger alone. This operation is especially applicable to children.

The Sluder Operation.—The technique of Sluder's guillotine operation is but a modification of that of the old-fashioned tonsillotomy. In the latter operation only the epithelial face of the tonsil, or the portion that projected beyond the pillars, was cut away, since it was all that could be forced through the fenestra of the guillotine. Pedunculated tonsils were often removed *in toto* by this method. Sluder's technique enables the operator to remove with the guillotine a large percentage of all tonsils, pedunculated or buried, in capsule by taking advantage of the free movability of the tissues of the sinus tonsillaris, and of the bony prominence of the posterior extremity of the alveolar process of the lower jaw. The tonsil is usually loosely attached to the walls of the sinus tonsillaris, to which it bears the relation of a slightly opened bud to its calyx. If the ring of a

guillotine is placed around the tonsil and pressed outward it tends to peel the calyx back and to unbutton the tonsillar bud from it. The bony surface at the angle of the jaw is not usually sufficiently prominent to effect this unbuttoning and to push the tonsil through the opening of the instrument. To gain this result the tonsil, after being partially engaged in the fenestra, is brought forward and slightly upward until its root or capsular surface rests over the bony prominence of the posterior part of the alveolus (the alveola eminence of the mandible [Sluder]). With this bony projection on its outer side, pressure outward with the ring of the guillotine produces a complete evulsion of the tonsillar bud from its calyx. It is then as easily removed in capsule by closure of the instrument as is the prominent pedunculated tonsil.

The *guillotine of Sluder* is a modification of the Mackenzie instrument. Greater strength is needed because of the force used in engaging the tonsil in the aperture, and this is gained by doubling the thickness of the shaft. Greater leverage is obtained by lengthening the handle and shortening the shaft. The knife edge is dull so that it may follow the line of cleavage between the tonsil and the capsule rather than cut through the tissues. The chances of hemorrhage are much reduced by this change. The aperture is elliptical with long axis transverse to that of the shaft. This modification is important, as the circular opening does not hug the tonsil closely and allows some of the surrounding tissues to leak through and to be cut away with the closure of the knife. This particularly applies to the anterior pillar. For the same reason the operator should have two guillotines, one with an aperture of 2.5 cm. by 1.8 cm., the other 1.75 cm. by 1.5 cm. (Sluder.)

Technique.—Sluder describes his operation as follows:[1]

[1] Transactions of the Amer. Laryn., Rhinol., and Otol. Soc., 1912.

Fig. 34.

The Sluder Guillotine (Sauer's modification).

"With my method one must approach the tonsil at an angle, approximately 45°, which requires the shaft of the instrument to cross the mouth entirely from the opposite side. This necessitates the distal side of the shaft being applied to the tonsil. It at the same time has the great advantage of leaving the lateral portion of the field of operation wide open for view and the use of the fingers of the other hand. Having the blade ground far back widens it further. (The use of the proximal side will be found exceedingly awkward or even impossible, as the surgeon's hands are interfered with and the lateral portion of the field of operation covered from view.)

"It is a very great advantage to operate on the right tonsil by holding the guillotine in the right hand and on the left tonsil by holding it in the left hand. If the surgeon can use only one hand, the position of the patient should be recumbent. Assuming that he uses his right hand for both tonsils and stands on the patient's right: for the right one he faces the patient's head; for the left one he must turn around so that he faces the patient's feet, and stand somewhat beyond (above) his head. (These relations might be sustained in the erect posture also.) The head should be held firmly by an assistant to prevent rotation, and the mouth kept fully open by a gag.

"Regardless of what may be the position of the patient's head, the surgeon takes his bearings from the lower jaw. The guillotine, with the transverse axis of the aperture vertical, is introduced into the mouth at an angle of 45° outward and backward, passing back until the distal arc of the aperture is completely behind the tonsil. The direction of the shaft is then changed to point downward in order to get the ring of the aperture under the lowermost part of the tonsil. The instrument at this moment may sometimes be rotated slightly by turning the handle downward (toward

LANE LIBRARY. STANFORD UNIVERSITY

the feet). This tends to enlarge the field of vision. It is then pressed outward until the distal arc of the aperture has been pressed against the ramus of the jaw, or, in case the patient is not anesthetized, against the firmly contracted internal pterygoid muscle which is inserted here. It is now brought slightly forward and upward, but held firmly against the bone and muscle, when it will be seen that the lower distal arc of the aperture has acted very much like a scoop, having secured the lower part of the tonsil and brought it forward and upward into the neighborhood of the alveolar eminence. In case the shaft has been rotated to secure its lower part, it is now put back into its original position by turning the handle upward. The upper portion of the tonsil is usually put into the grasp of the distal arc of the aperture by this rotation. If the tonsil is not too large and flat (thin), it is usually secured, both lower and upper portions, in the first setting of the guillotine and no rotation is needed. The distal arc of the aperture is now firmly held behind the posterior border of the tonsil, and the instrument drawn forward and upward at an angle approximately 45°, which will be found to have pulled it upward and forward into the eminence of the alveolus. The blade is now pushed down with the gentlest possible pressure until the surgeon sees that it is in contact with the tissues. It should not be pressed forcibly until the parts are engaged satisfactorily in the aperture. The blade, being in contact with the tissues, prevents the portion of the tonsil which has gone through from slipping out again.

"At this moment the surgeon may perceive that although the distal arc of the aperture is entirely behind and external to the tonsil, a part of its anterior portion has still not gone through. This is usually readily seen, but may more definitely be determined by feeling with the tip of the index finger of the other hand and at the same time it may be

pushed through. This is done by the gentlest massage—simply stroking it in the direction of the aperture with the ball of the index finger and, at the same time, pushing the blade very gently across the remaining portion of the aperture. When the last of the anterior portion has gone through it may be readily seen as a rule; but may be determined with great accuracy by feeling with the ball of the index finger—pushing it up and down over the end of the blade as it closes the aperture. If all of the tonsil has gone through, the distal arc will be felt smooth and firm and be covered by what seems to be a thick mucous membrane (it is of course two layers of membrane). If a part of the tonsil has not gone through, it can easily be felt and recognized as a mass of tissue harder than membrane and usually irregular.

"All of the tonsil having gone through, the blade is now pushed across with all the power of the surgeon's hands. Great pressure is usually required because the blade has been made dull. If it be too dull, or if it does not fit perfectly into the soft metal lining of the distal arc of the aperture, it will not cut altogether through. The instrument must then be pulled forward a little and its end be stripped off with the finger of the other hand. This does not delay the operation. It may possibly make a little more subsequent pain, but I am by no means sure that it does."

If the operator does not happen to be a powerful individual he will have difficulty in many of his cases in pushing the blade of the guillotine home. This difficulty is obviated by the use of the Sauer modification of the Sluder instrument. This has a screw attachment which is put into gear after a partial closure of the blade has caught the tonsil in the correct position. The blade then acts as an écraseur.

Treatment of the Operative Wound.—Whatever method is used in removing the tonsil, the subsequent treatment of

the operative wound is the same. A gauze sponge of a size that will fit snugly into the sinus should be inserted on the end of a long sponge holder passing from the opposite corner of the mouth, so that firm pressure may be exerted outward and backward. The fingers placed under the angle of the jaw make ample counter-pressure. The sinus should then be carefully inspected for bleeding points, and if any are found they may receive attention while the patient is yet under the anesthetic. The sinus should be practically dry before the patient leaves the operating room, though slight oozing may be disregarded. If it is present, the glyceride of tannin applied to the sinus on a sponge helps to stop it. Many of the so-called delayed hemorrhages are in reality primary in character, and may be found at the time of operation if the foregoing precautions are used. It is much easier and certainly more comfortable to the surgeon to treat them then and there than to be obliged to have the patient re-etherized later and after the loss of a considerable quantity of blood. The naso-pharynx should always be examined after a tonsillectomy, and if any adenoid is present it should be removed. This should not be done, however, until the operator has satisfied himself that there is no bleeding from the sinus tonsillaris, as it is not easy to determine this if there is free bleeding from the naso-pharynx.

Post-Operative Treatment.—The patient should be kept in the hospital and in bed for at least twenty-four hours after the operation. This is not as essential in children as in adults, since post-operative hemorrhage unless immediate is very rare in them. In private practice it is a good rule for all cases. During the first day nothing but cold liquid food should be taken. After that the amount and character of the food depends largely on the amount of discomfort that the patient has in swallowing, though coarse irritating

articles should be avoided until the throat has practically healed. No gargle is usually to be advised, but the mouth should be kept thoroughly clean with an alkaline wash. The soreness of the throat after tonsillectomy varies tremendously with the individual. Some patients experience only mild discomfort which passes away after three or four days, to such an extent at least that they no longer mind it. With others the soreness lasts for a week or ten days and is very distressing. This difference cannot usually be ascribed to the different types of operation, but rather to individual idiosyncrasy; though in general I think that it is true that the less the throat is bruised by the pressure of instrumentation, the less will be the subsequent pain. The size of the root of the tonsil is also an important factor, especially the amount of the anterior surface of the posterior pillar that it covers and which in consequence is denuded of mucosa during the operation.

CHAPTER X.

COMPLICATIONS AND SEQUELÆ OF OPERATIONS ON THE TONSILS.

Hemorrhage.—Of all the complications of tonsil operations this has generally been regarded as the most serious. While it cannot be said to be of rare occurrence, especially in the adult, it is not sufficiently common to be seriously apprehended in the individual case. Even if it does occur, the cases in which it cannot be absolutely and easily controlled are extremely rare. This statement is made advisedly. It presupposes a number of conditions,—first, that the patient is not hemophilic; second, that the operation is done by a careful and competent throat surgeon and not by a general practitioner of medicine; and third, that the patient is in a hospital and that he remains there for at least twenty-four hours after the operation. If all these conditions are present, and they always should be, the chances of fatal result ensuing from this cause are so slight as almost to be a negligible factor.

Occurrence.—No reliable statistics are available for the old operation of tonsillotomy. The general impression seems to be that it occurred somewhat less frequently than after enucleation. This is probably due largely to the fact that since tonsillectomy began to be a routine procedure the pathological consideration of certain infections being of tonsillar origin has been the cause of a tremendous increase in the number of cases operated upon. However this may be, it is certain that the primary hemorrhage after tonsillectomy is as nothing compared to that following partial

removal of the tonsil. The average careful dissection of the tonsil comes close to being a bloodless affair. As I have remarked elsewhere, the sheet wrapped around the patient is often unstained until after the adenoid of the vault is removed.

Accurate figures showing the incidence of hemorrhage after tonsillectomy are easily obtained. In seven hundred consecutive cases in children of the straight knife and snare dissection done during my service at the Boston Dispensary in the past five years, only two hemorrhages have occurred that required sewing of the faucial pillars. In one hundred and forty consecutive tonsillectomies by the same method, done on patients over sixteen years of age at the Massachusetts General Hospital there were four hemorrhages that required suturing of the pillars. The bleeding was readily controlled in all cases by this method. While these statistics cannot be taken as an accurate measure of the number of hemorrhages that will occur in any given series of cases, they nevertheless give a definite idea of the average incidence of bleeding after tonsillectomy both in children and in the adult.

Types of Tonsillar Hemorrhage.—Tonsillar hemorrhage may be primary, delayed or secondary, venous or arterial. *Primary hemorrhage* is that which occurs at the time of the operation. It is usually comparatively slight in tonsillectomy, but profuse in tonsillotomy. *Delayed hemorrhage* is that which occurs at any time during the first forty-eight hours after the operation. It usually is discovered during the first six hours and in many cases is nothing more than a primary bleeding that was disregarded at the time of the operation and which has failed to stop. Delayed hemorrhage of this sort should never occur, as all primary bleeding should be controlled before the patient leaves the operating room. It may, however, result from a fresh

opening of the cut ends of blood vessels during the gagging and vomiting following ether. The act of swallowing may of course produce the same effect; but much less violence is done to the denuded muscular walls of the sinus than occurs during vomiting, which also causes a sudden high pressure in the blood vessels of the head that may be sufficient to start a fresh bleeding. For this reason hemorrhage later than the first few hours after operation is extremely rare. *Secondary hemorrhage* is that due to the opening of vessels during the separation of the slough from the walls of the sinus tonsillaris. It may occur at any time after the second day, but is most common on the fifth, sixth and seventh days. It has been reported as late as the fifteenth day. Under any circumstance it is a very rare occurrence, but its gravity makes imperative the only measures that may be taken to prevent it,—a clean dissection of the tonsil which leaves no bruised and macerated tissues behind and the avoidance of anything that may forcibly remove the slough from the sinus wall, such as very hot or coarse food or too frequent gargling of the throat. The majority of the late hemorrhages that have been reported have followed either a tonsillotomy or a galvano-cautery snare operation. In either the chances of a piece of sloughing tissue being left in the sinus are much greater than is the case in dissection enucleation in which the sinus walls are left perfectly clean and with little chance for sloughing to take place.

Venous hemorrhage occurs usually from the large vein in the posterior external angle of the sinus or from the plexus at the base near the lingual tonsil. The anterior vein is not so apt to give trouble. These veins never bleed unless the sinus wall is injured. For this reason the use of the right-angle knife for dissection is to be deprecated, especially between the tonsil and the posterior pillar. Also, the ring

punch should be used with great discretion near the base of the sinus. I have seen a number of profuse hemorrhages follow both these procedures. *Arterial hemorrhage* occurs most often in the lower half of the sinus, either from one of the twigs in the anterior or posterior pillars or from the larger vessels of the external wall derived from the facial artery. Occasionally an arterial twig in either pillar above the middle line spurts freely. The arterial bleeding from the pillars may always be seen as distinct spurters; that from the base between the pillars more often shows as a constant welling of blood, though spurters are not uncommonly seen here. I have never seen the superior artery of the tonsil bleed freely enough to require attention.

Causes of Hemorrhage.—Hemophilia, arteriosclerosis, fibrous hypertrophy of the tonsil, marked adhesions between the capsule and the muscular walls of the sinus are the principal predisposing causes of hemorrhage. Wounding or bruising of the sinus wall are direct causes.

Prophylaxis.—Hemophilia should always be ruled out as far as is possible by history. If there is any doubt, the coagulation time of the blood may be taken and if found to be above normal (7½ minutes) measures may be taken to reduce it, either by the administration of calcium lactate, fifteen grains t. i. d., or by the subcutaneous or intravenous injection of fresh rabbit serum. No known case of hemophilia should be operated on under any circumstance. The only prophylactic measures that may be taken against the other causes of hemorrhage are a careful and skillful operation and a well-equipped hospital within easy access of the operator. No other precaution is worth so much as this last which puts the surgeon in a position to treat effectually any hemorrhage that may occur.

Treatment.—The necessity of making sure that primary hemorrhage has ceased before the patient leaves the operat-

ing room has already been mentioned. If this bleeding proves severe and protracted, its treatment differs in no way from that of delayed or secondary hemorrhage. In dealing with post-operative tonsillar hemorrhage, three methods are available, short of tying the external carotid artery. Exigencies requiring the latter procedure must be extremely rare, for in the last five years, during which tonsillectomy has been the rule at the Massachusetts General Hospital, there has been no case in which it was even thought of. These methods will be taken up in the order of their simplicity, and it is in that order that I think they should be tried in any given case.

Simple Pressure.—Ether should be given in all cases, as it is useless to attempt to do anything without it if the bleeding is at all severe; the patient soon becomes panic-stricken and is then unmanageable. The upright position with the head forward, so that the blood is not swallowed nor inhaled but runs out of the mouth and into the ether cone, is essential. With the mouth-gag in place, a curved sponge holder with a gauze sponge at the end, of a size to fit snugly into the sinus tonsillaris, is inserted between the pillars of the bleeding side and pressed strongly outward and slightly backward; at the same time counter-pressure with the fingers is applied just behind the angle of the jaw. The sponge on the inside may easily be grasped with the fingers on the outside, and thus a very effective pressure is brought to bear over the entire surface of the tonsillar fossa. Most of the more moderate hemorrhages may be completely controlled in this way. If after a few minutes pressure the bleeding is not stopped, no time should be lost in passing on to the next method.

Ligation of the Bleeding Point or Points.—Pressure should be applied as in the first method described, as in this way the exact bleeding point is more likely to be found. If

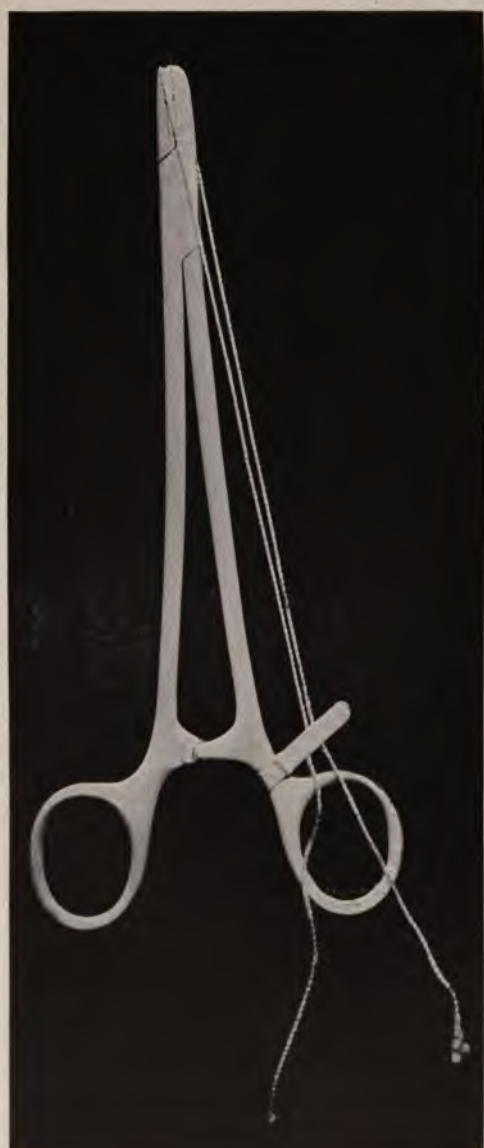

Fig. 35.

Schoemaker's artery forceps.

this can be determined it may be grasped with a hemostat and ligated. As it is extremely difficult to place the ligature beyond the end of an ordinary artery forceps, the Schoemaker hemostat, which carries the ligature in a notch at the end of one of the blades, will be found to be of service in these cases.

Suturing of the Faucial Pillars.—In cases of severe bleeding, whether or not it is stopped by simple pressure, unless it may be distinctly located and the bleeding point securely ligated, the faucial pillars should be sutured. This does not mean merely sewing their edges together, which does more harm than good, as a blind space is created into

Fig. 36.

Diagrams showing the correct and incorrect position of sutures.

which the bleeding still continues; nor is the presence of a gauze sponge in this space desirable. The success of the operation depends on the obliteration of the sinus tonsillaris. Consequently the sutures must pass completely around the sinus, as they are shown in the diagram (Fig. 36). When so placed and tied they will control any hemorrhage, provided of course that the patient is not hemophilic and that no undue injury has been done to the surrounding tissues during the removal of the tonsil.

Technique of Suturing the Faucial Pillars.—Two or three long-handled hemostats, a long needle-holder and a large and strong half-curved needle threaded with catgut are the

only special instruments required, though Mosher's aneurism needles and special suture carrier are a great help. The chief difficulty of the operation lies in passing the needle completely round the sinus, without including in its sweep too large an amount of the surrounding tissues. This is accomplished by grasping the outer sinus wall at about its central point with one of the long hemostats and having an assistant gently pull it inward while the needle is being placed. The depth of the sinus is so much decreased by this measure that there is no difficulty in passing the needle completely around it and in such a way that the suture will include only a moderate amount of the faucial tissue. The first suture should be placed near the base of the sinus. The needle is passed horizontally from behind forwards, entering the posterior pillar and coming out on the anterior surface of the anterior pillar near its inner edge. At no place should the needle come to the surface of the sinus. This one suture will be found to be all that is necessary if the hemorrhage is from the lower quarter of the sinus. It brings pressure to bear directly on the venous plexus at the base, the lower part of the large vein of the posterior wall and upon the most important of the arteries of the external wall. One or two sutures may be placed higher up as necessity demands. If the sutures are of silk, they should be removed at the end of twenty-four hours; if of catgut they may be ignored as they soften and break away after the first day or two. It is never well to leave the pillars in close apposition longer than that, as permanent adhesions are not desirable. To a certain extent this cannot be avoided in these cases; but if the sutures be removed early, the subsequent unpleasant sensations due to adhesions will be avoided. Michel's metal clamps may be substituted for the ligature. They are satisfactory in many cases, being extremely easy to put on. Their removal is sometimes dif-

Fig. 37.

Mosher's Aneurism Needle and Suture Carrier for suturing the faucial pillars. Separate needles are necessary for the right and the left side.

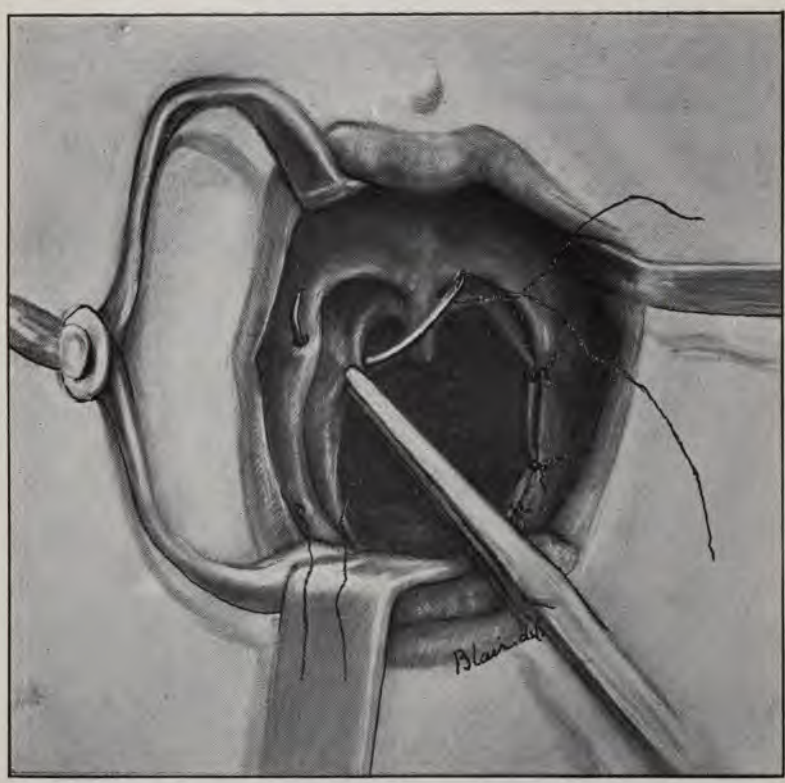

Fig. 38.

Suturing the faucial pillars. This drawing may give the impression that the suture is being placed too superficially. This is really not the case as the external sinus wall is being pulled inward so as to greatly reduce the depth of the sinus. With this technique one does not have to include the whole width of the pillars in the suture.

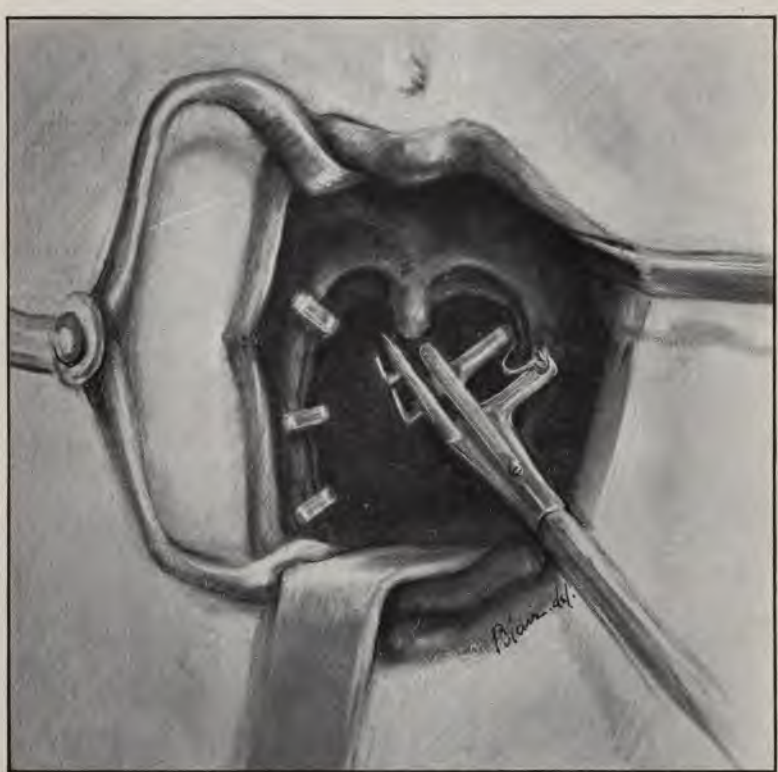

Fig. 39.

Michel's metal clamps for the control of tonsillar hemorrhage being placed in position. The clamps should be much longer than those shown in the drawing so that they may include a much greater breadth of the pillars.

ficult. If the sinus is deep they may not compress its outermost parts. Under such circumstances a small gauze sponge may be inserted between the pillars and the desired pressure obtained in this way.

If none of the foregoing methods are successful in stopping the hemorrhage, hemophilia should be suspected. Fresh rabbit serum, or if this cannot be obtained, diphtheria antitoxin should be injected intravenously (10 to 15 c.c.). There is, of course, danger of an anaphylactic reaction in case the antitoxin is used in this way and the patient should at any subsequent time require an injection for the treatment of diphtheria. No such danger attends the use of the rabbit serum. As a last resort, direct transfusion combined with ligation of the external carotid should be tried.

Septic Infection.—Septic infection of mild degree is not uncommon after operations on the tonsils. The symptoms are slight, the patient being somewhat indisposed and running a temperature of 101° to 104° for a variable time. These symptoms usually subside completely within a week or ten days. Neither the heart nor joints are involved. More rarely cardiac or arthritic lesions develop and the period of convalescence is prolonged, recovery at the end of three or four weeks being the rule. Existing joint or heart conditions not infrequently show distinct exacerbation following removal of the tonsils. Non-suppurative glands of the neck occasionally suppurate as a result of the operation. Infections of mild degree would probably be reported more often if patients were kept under close observation for a longer period of time. It is undoubtedly true that most operators pay but slight attention to symptoms other than those directly connected with the throat unless such symptoms are severe or protracted. In large hospital

clinics patients are usually lost sight of after the first two or three days following the operation. All patients, especially children, should be examined at the end of three or four days and again when the post-operative exudate has disappeared. The discovery of a mild endocarditis at this time and its proper rest treatment may add much to the subsequent physical well-being of the patient.

Severe septic infection following operations on the tonsils are fortunately rare. During the past five years I have not seen a single case either at the Massachusetts General Hospital or the Boston Dispensary, in both of which hospitals the number of tonsil and adenoid operations is very large. They occasionally occur, however, and may take the form of a severe hematogenous infection with destructive blood changes; or a malignant endocarditis may supervene with fatal result. Koplik [1] has reported instances of both these types of infection. An old standing mitral lesion and chorea were present at the time of operation in his case of malignant endocarditis; a condition which Rosenow has shown experimentally to be favorable to the development of ulcerative vegetative lesions of the endocardium whenever the valves become infected a second time with the common endocarditic coccus (streptococcus viridans). Abscess of the lung has been reported following tonsil operations.

When one considers the conditions in the throat after tonsil operations,—extensive wounds which must of necessity be contaminated both by the organisms of the pharynx and by those of the tonsillar crypts—the wonder is, not that septic infection occasionally occurs but that so many patients escape it altogether. That the wounds are open and therefore drain perfectly, probably accounts largely for this general immunity. The condition of the patient is

1 Infections Following Tonsillotomy, etc. Amer. Jour. Med. Sciences, July, 1912.

also an important factor and for that reason should be brought to as high a level as possible before the operation. In cases of systemic infection of tonsillar origin, however, the operation itself is the one therapeutic measure that may be expected to accomplish much in this direction; and although exacerbation of the symptoms may ensue it is not wise to defer the operation indefinitely. A period of comparative freedom from symptoms should be chosen.

The character of the operation influences markedly the local septic conditions that follow, and for that reason it may be considered an important element in determining the degree of septic absorption that may follow removal of the tonsils. Any operation that leaves ragged tags of bruised and devitalized tissue in the sinus tonsillaris is to be deprecated, as such tags always become the seat of more or less extensive septic sloughs. The too vigorous use of a metal dissector in turning out the superior lobe from its palatal bed often causes extensive ecchymoses in the sinus walls. As I have pointed out before, the dissection of this part of the tonsil should be done with a sharp knife if there is much difficulty in effecting it with the blunt dissector. The use of the snare to complete the dissection does not cause any harmful sloughing of the tissues, as the wire simply follows the line of least resistance.

Prophylactic measures readily suggest themselves and should be carried out in all cases. No acutely inflamed tonsil should be removed. The crypts should be emptied of all obvious debris, and the pharynx and mouth put into as good a condition as possible by the use of alkaline washes and gargles. The antiseptic properties of such washes are so mild as to be of little or no importance; they act simply as cleansing agents and as such have a distinct value. If the condition of the teeth or gums is bad it should be corrected for two reasons: first, because streptococci are

numerous in carious teeth and in the lesions of pyorrhœa alveolaris, and such foci in the mouth materially affect the bacterial content of the pharynx; and second, if the proposed operation is for the relief of systemic disturbances, the teeth or gums are quite as likely to be the primary focus as the tonsils.

Post-Operative Diphtheria.—Diphtheria following operations on the tonsils is occasionally reported. As is well known, the Klebs-Loeffler bacillus is present in the throat in 2 to 3 per cent. of normal persons who have not been in contact with the disease. The proportion increases rapidly in groups of individuals who have been directly exposed, the percentage being in direct proportion to the intimacy of the contact. The organisms are usually found only on the pharyngeal surface. In some cases they invade the tonsillar crypts and thrive there without causing any lesion. Post-operative diphtheria, therefore, may be due to organisms present in the pharynx or the crypts of the tonsils before the operation; or the bacilli may be taken in through the mouth or nose after the operation and implanted on the denuded surface of the tonsillar sinuses. The incidence of this infection is so rare that only very obvious precautions against exposure, both before and after operation, may be taken to prevent it. Children should not be allowed to attend school or to mingle indiscriminately with companions until the throat has practically healed. In large public clinics in which appointments for operation are made weeks in advance, it is important that the throat should always be examined before the anesthetic is given; otherwise it is not impossible that a child may be operated on who at the time has a beginning diphtheria.

Diphtheria Carriers.—The relation of the tonsils to the so-called diphtheria carriers is an interesting one. The Klebs-Loeffler bacilli on the surface are probably of slight

importance, for unless this supply is kept up from some hidden source, such as the crypts of the tonsils, the adenoid of the vault or the nasal accessory sinuses, they are probably only temporarily present. In the crypts they may flourish indefinitely. They are probably not usually virulent to the host but may be a source of danger to others. In those cases in which cultures from the throat remain positive for a long period after all clinical manifestations of diphtheria have disappeared, tonsillectomy may relieve the condition. The danger of infection to the patient is slight.

Post-Operative Deformities.—In uncomplicated cases, deformities of the palate and the faucial pillars should never occur. If the sinus tonsillaris is deep and the tonsillar root extensive, the surface denuded by the removal of the tonsil will include nearly the whole of the sinus even to the edges of the faucial pillars. Under these circumstances contraction of the cicatrix may pull the pillars so closely together that they appear to be adherent. There is no deformity, but the pillars do not stand out with a distinct gutter between them. Beyond slight sensations of pulling which subside after a few weeks, this causes no symptoms. I have never seen a case in which either the speaking or the singing voice was affected by it. Immediately after the operation the arch of the palate may be slightly higher on one side than on the other, since one tonsil may have mounded higher into the palate than the other. The inequality becomes scarcely noticeable after healing is complete. In adults, after repeated attacks of peritonsillar inflammation, or when bone or cartilage are present in the capsule, the dissection of the tonsil is sometimes so difficult that a certain amount of inequality of the palatal arches may be expected. Even here it should not be such as to be classed as a deformity. Careless or incompetent operat-

ing may be followed by almost any degree of deformity of the palate and the faucial pillars, from loss of the uvula to conditions which only specific adhesions and contractions can duplicate.

The Effects of Tonsillectomy on the Singing Voice.—Provided that no undue injury is done to the palate or to the faucial arches, the singing voice is not injured by the radical removal of the tonsils. On the contrary, a marked improvement often results. Any injury of the pillars that results in cicatricial contraction interfering with the movements of the palato-pharyngeus muscle; or any injury that leaves the palate less free than normal in its backward and forward play, has a distinctly deleterious effect on the voice. The function of the palato-pharyngeus muscle is to tilt the thyroid upon the crycoid cartilage, thereby stretching the cords. It is, therefore, an important regulator of the pitch of the voice. Cicatricial contractions between the pillars may so interfere with its movements that the quality and pitch of the voice, especially of its higher tones, may be materially modified. In discussing this question, however, we assume that the integrity of the palate and the pillars has not been affected by the operation. With this condition fulfilled, I have seen nothing but benefit to the voice result from the operation.

INDEX

INDEX

A

Abscess of the tonsil:
  acute, 87
  chronic, 99
Abscess, peritonsillar, 88
  complications in, 91
  duration of, 91
  etiology of, 89
  symptoms of, 90
  treatment of, 92
Adenitis, cervical, 37
  secondary to tuberculosis of the tonsil, 75
  simple inflammatory, 71
  sources of infection in, 37, 38
  tubercular, 71
Adenoids:
  diagnosis of, 118
  etiology of, 115
  operation on by direct method, 123
  pathology of, 116
  prognosis in, 119
  regeneration after removal, 123
  symptoms of, 117
  treatment of, 121
Angioma of the tonsil, 125
Appendicitis, secondary to tonsillar infection, 71
Arthritis, acute, chronic, of tonsillar origin, 70
Atrophy of the tonsil, 48

B

Bacillus fusiformis:
  occurrence in lesions of Vincent's angina, 94
  description of, 94
Blood supply of the tonsil:
  arteries, 35
  veins, 35

C

Calculus of the tonsil, 100

Capsule of the tonsil, 33
bone in, 42
cartilage in, 42
glands mucous, in, 42
histology of, 42
Capsule, development of, 27
Carotid artery, internal, relation to the tonsil, 41
Carcinoma of the tonsil, 126
Cervical lymphatics, description of, 37, 38
Chorea, 71
tonsils and adenoids as foci of infection in, 75
Colon bacillus:
presence in tonsillar infection, 78
Crypts, 30
bacteriology of, 66
debris of, 65
description of, 30
development of, 22
relation to the capsule, 41
Cyst of the tonsil, 100

D

Diphtheria:
bacillus of, in normal tonsils, 67
post-operative, 158
relation of the tonsils to diphtheria carriers, 158

E

Enchondroma of the tonsil, 125
Endocarditis, secondary to tonsillar infection, 70
Epithelium of the tonsillar crypts, 43
changes in, with age, 44, 49

F

Faucial pillars:
suturing of, for post-operative tonsillar hemorrhage, 153
Fibroma of the tonsil, 125
Fold, intratonsillar, 22
Fossa:
anterior, 33
posterior, 33
supratonsillar, development of, 26
Function of the tonsils, 55

H

Hyperkeratosis tonsillaris, 101
etiology of, 101
pathology of, 103

Hyperkeratosis tonsillaris—*Continued.*
symptoms of, 104
treatment of, 105
of the lingual tonsil, 112
Hypertrophy of the tonsil, 44
causes of, 47

I

Infection:
age, relation of to tonsil infection, 76
septic, after tonsillectomy, 155
systemic, relation of the tonsils to, 70

J

Jaundice, infectious, secondary to tonsillar infection, 71

K

Klebs-Loeffler bacillus:
occurrence of in normal tonsils, 67

L

Lénárt, Z.:
injection experiments to demonstrate lymphatic connection between nose and tonsil, 59
Lingual tonsils:
abscess formation under capsule of, 112
chronic retention in crypts of, 112
hypertrophy of, 111
hyperkeratosis of, 112
Lipoma of the tonsil, 125
Lymphoblasts, 18
Lymphatics of the tonsil, 36
cervical, description of, 37, 38
Lymphoid follicle, histology of, 18
Lymphoid tissue:
development, 23
general nature, 17
histogenesis of, 28

N

Neoplasms of the tonsil:
benign, 124
treatment of, 125
malignant, 125

Neoplasms of the tonsil, malignant—*Continued.*
treatment of, 127
Nephritis, secondary to tonsillar infection, 70
Nerve supply of tonsils, 39
Neuritis, secondary to tonsillar infection, 71

P

Palate, deformities of after tonsillectomy, 159
Papilloma of the tonsil, 124
Pathology of the tonsils, general, 63
Pharyngo-maxillary space, its relation to the tonsil, 40
Pharyngo-mycosis, 101
Pharyngeal tonsil (*see* also adenoids):
crypts of, 51
epithelium of, 52
mucous glands in, 51
Pharynx:
lateral folds of, 113
abscess formation beneath, 113
histology of, 52
treatment of pathological conditions in, 113
posterior wall, lymphoid nodules of, 52
treatment of pathological conditions in, 113
Plasma cells, in tonsils, 19, 64
in acute tonsillitis, 80
Plica, 30
anterior, 26
attached, 27
retrotonsillaris, 22, 32
supratonsillaris, 33
triangularis, formation of, 21

Q

Quinsy sore throat (*see* abscess, peritonsillar)

R

Relation of the tonsils, 39
Retterer, theory of genesis of lymphocytes in the tonsil, 28
Rheumatism, acute articular, relation to the tonsil, 71

S

Sarcoma of the tonsil, 127
Septic sore throat, 83
complications of, 86
diagnosis of, 87

Septic sore throat—*Continued.*
etiology of, 84
pathology of, 85
relation of milk supply to, 84
symptoms of, 86
treatment of, 87
Sinus tonsillaris:
description of, 30
formation of, 21
Streptococcus, 67
varieties of, their occurrence in the crypts of the tonsil, 67
Styloid process, relation to the capsule, 41
Syphilis of the tonsil, 108
primary, 108
diagnosis, 109
frequency, 108
symptoms, 108
secondary, 110
tertiary, 111
treatment, 108

T

Teeth, relation to hypertrophy of the tonsil, 47
Thornwaldt's disease, 123
Thyroid gland, accessory at the base of the tongue, 112
Tonsil, faucial:
atrophy of, 48
development of, 21
histogenesis of, 28
hypertrophy of, 44
normal histology of, 41
root of, 23, 32
types of, 34
Tonsil, lingual, 50
anatomy of, 50
histology of, 50
Tonsil, pharyngeal (*see also* adenoid), 51
anatomy of, 51
histology of, 51
Tonsillar tubercle, 21
Tonsillitis, chronic, 98
symptoms of, 98
treatment of, 101
Tonsillitis, acute follicular:
complications of, 81
diagnosis of, 81
etiology of, 78
pathology of, 79

Tonsillitis, acute follicular—*Continued*
symptoms of, 80
treatment of, 82
Tonsillitis, acute lingual, 112
treatment of, 82
Tonsillectomy:
anesthesia in, 134
general, 135
local, 134
dissection operation in, 137
effects on the singing voice, 160
finger dissection in, 141
hemorrhage after:
causes of, 151
frequency of, 148
prophylaxis, 151
treatment of, 151
types of, 149
indications for, 131
position of patient in, 136
post-operative treatment, 146
preparation of patient for, 135
Sluder operation, 141
Tonsillotomy:
indication for, 130
technique of, 130
Toxemia, chronic, relation of tonsils to, 71
Trabeculæ, histology of, 42
Tuberculosis, of the tonsils, latent, 105
pulmonary, tonsils as infecting source in, 75, 76

V

Vincent's angina, 93

LANE MEDICAL LIBRARY
300 PASTEUR DRIVE
PALO ALTO, CALIFORNIA 94304
Ignorance of Library's rules does not exempt
violators from penalties.

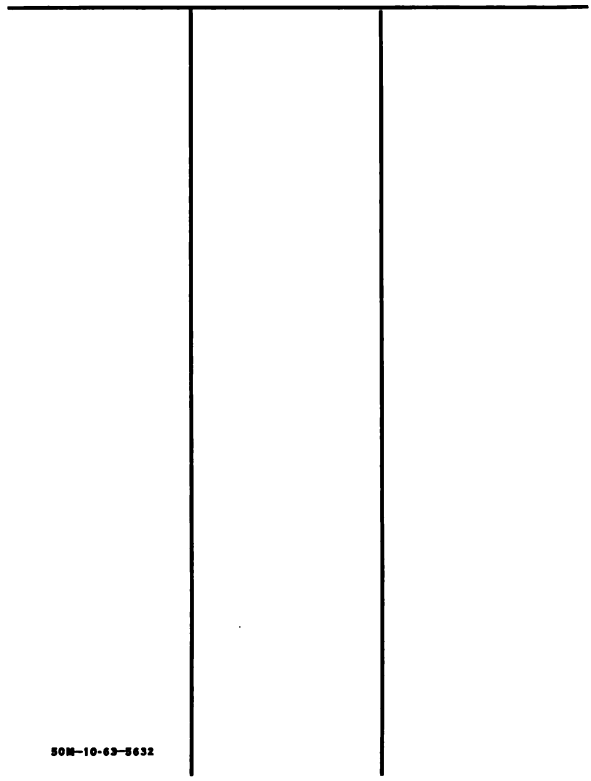

50M-10-63-5632

LANE MEDICAL LIBRARY
300 PASTEUR DRIVE
PALO ALTO, CALIFORNIA 9430

R565 Barnes, H.A. 40483
B26 The tonsils
1914

NAME	DATE DUE
Shalumar	JAN 28 1937
Frederic P. Shidler	[illegible]
	JUL 16 1937
Emery Leivers	SEP 17 1937
C O Bulitot	JUN 27
[illegible]	JUL 29
J W Arnold	DEC
A S Rochwell	JUN

R565
B26
1914